

**RADIATION
PROTECTION:
CONE BEAM CT FOR
DENTAL AND
MAXILLOFACIAL
RADIOLOGY**

**Evidence Based Guidelines
2011**
(v2.0 Final)

SEDENTEX CT

RADIATION PROTECTION: CONE BEAM CT FOR DENTAL AND MAXILLOFACIAL RADIOLOGY

Evidence based guidelines

A report prepared by the SEDENTEXCT project
www.sedentexct.eu

2011



The SEDENTEXCT project (2008-2011) is supported by The Seventh Framework Programme of the European Atomic Energy Community (Euratom) for nuclear research and training activities (2007 to 2011) <http://cordis.europa.eu/fp7/euratom/>.

Neither the European Commission nor any person acting on behalf of the Commission is responsible for the use that might be made of the following information. The views expressed in this publication/document/guidelines are the sole responsibility of the author and do not necessarily reflect the views of the European Commission.

PREFACE

SEDENTEXCT was a collaborative project that aimed to acquire key information necessary for sound and scientifically based clinical use of Cone Beam Computed Tomography (CBCT) in dental and maxillofacial imaging. In order that safety and efficacy are assured and enhanced in the “real world”, a parallel aim was to use this information to develop evidence-based guidelines dealing with justification, optimisation and referral criteria for users of dental CBCT. The aim of this document is to provide such evidence-based guidelines to professional groups involved with CBCT in dental and maxillofacial imaging, including:

- Dental and Maxillofacial Radiologists
- Dentists working in primary care and their assistants
- Radiographers/ Imaging technicians
- Medical Physicists
- Equipment manufacturers and suppliers

The core guidance in preparing the document has been from the two relevant Council Directives of the European Union:

- Directive 96/29/Euratom, of 13 May 1996, laying down the basic safety standards for the protection of the health of workers and the general public against the dangers arising from ionising radiation (Basic Safety Standards Directive)
- Directive 97/43/Euratom, of 3 June 1997, on health protection of individuals against the dangers of ionising radiation in relation to medical exposure (Medical Exposures Directive)

Beyond these sources, the detailed guidelines have been prepared by systematic review of the currently available literature. No exposure to X-rays can be regarded as completely free of risk, so the use of dental CBCT by practitioners implies a responsibility to ensure appropriate protection.

This document supersedes the Provisional Guideline document published in May 2009, incorporating new research, including work carried out within the SEDENTEXCT project itself.

Guidelines are not a rigid constraint on clinical practice. Local variations will be required according to national legislation, healthcare provision and practice and the unique clinical circumstances of patients.

I hope that the document will be of help to professional groups and contribute to optimizing the use of ionizing radiation in dental imaging.

K. HORNER
SEDENTEXCT project Co-ordinator

CONTENTS

	Page
Preface	3
Contents	4
SEDENTEXCT project members	6
Guideline Development Panel Members	8
Acknowledgments	9
Foreword	10
1 Introduction and guideline development	11
Imaging in dentistry and the dental and maxillofacial Specialties	11
Guideline development	11
Future guideline review	17
References	18
2 Radiation dose and risk	19
X-rays	19
Radiation damage	19
Radiation dose	19
Radiation risk	20
Doses and risks with CBCT	21
References	24
3 Basic Principles	27
Background	27
Methodology	27
The “Basic Principles”	28
References	29
4 Justification and referral criteria	30
Introduction	30
References	32
The Developing Dentition	36
<i>Localised applications of CBCT for the developing dentition</i>	37
<i>Generalized application of CBCT for the developing dentition</i>	41
References	43
Restoring the Dentition	49
<i>Dental caries diagnosis</i>	49
<i>Periodontal assessment</i>	50
<i>Assessment of periapical disease</i>	51
<i>Endodontics</i>	53
<i>Dental trauma</i>	57
References	58
Surgical applications	63
<i>Exodontia</i>	63
<i>Implant dentistry</i>	65
<i>Bony pathosis</i>	68
<i>Facial trauma</i>	69

	<i>Orthognathic surgery</i>	70
	<i>Temporomandibular joint</i>	71
	References	72
5	CBCT equipment factors in the reduction of radiation risk to Patients	81
	X-ray tube voltage and mAs	81
	Field of View and collimation	82
	Filtration	83
	Digital detector	83
	Voxel size	84
	Number of projections	85
	Shielding devices	86
	References	86
6	Quality standards and quality assurance	89
	Quality assurance programme	89
	Equipment performance	89
	<i>Critical examination</i>	90
	<i>Acceptance and commissioning tests</i>	91
	<i>Routine tests</i>	91
	Patient Dose	92
	<i>Dose quantities</i>	92
	<i>Establishing DRLs</i>	93
	<i>Using DRLs</i>	94
	Clinical Image Quality Assessment	94
	<i>Comparison with standard reference images</i>	95
	<i>Reject analysis</i>	95
	<i>Audit against established clinical image quality criteria</i>	97
	References	99
7	Staff protection	100
	Classification of areas	100
	Design of the CBCT room	101
	<i>Protection for adjacent areas</i>	101
	<i>Room layout</i>	102
	Personal Monitoring	103
	References	103
8	Economic evaluation	105
	References	106
9	Training	107
	Roles and responsibilities	107
	Curricula for training in CBCT	108
	References	111
Appendix 1	Summary of recommendations	112
Appendix 2	Recommendations for research and development	119
Appendix 3	Glossary and abbreviations	122
Appendix 4	Quality Control Manual for dental CBCT systems	125

SEDENTEXCT PROJECT MEMBERS

The SEDENTEXCT consortium is a multidisciplinary team of seven partners, exploiting the synergies between medical physicists, dentists and dental radiologists, dentists, experts in guideline development and industry. In each centre, excluding the industrial partner, there is both dental and medical physics expertise. The Table below lists the participants.

Participant	Individuals
University of Manchester, UK	Keith Horner (<i>SEDENTEXCT Project Co-ordinator</i>) Gillian Armitt (<i>SEDENTEXCT Project Manager</i>) Vivian Rushton Hugh Devlin Stephen Birch Anne-Marie Glenn Chrysoula Theodorakou Anne Walker Ian Jacob Katie Howard Lorna Sweetman Mark Worrall Linda Norman Kevin O'Brien Mohammed Islam Helen McEvoy Gareth Hughes Jim Petch
National and Kapodistrian University of Athens, Greece	Kostas Tsiklakis (Senior scientist) Kety Nicopoulou-Karayianni Harry Stamatakis Anastasia Mitsea Giorgios Manousaridis Konstantina Alexiou Sofia Gavala Konstantinos Merdenisianos Pantelis Karabelas Katerina Donta
“Iuliu Hatieganu” University of Medicine and Pharmacy in Cluj-Napoca, Romania	Mihaela Hedesiu (Senior scientist) Mihaela Baciut Grigore Baciut Horatiu Rotaru Simion Bran Cristian Dinu Bogdan Crisan Sorana Bolboaca Dan Gheban Andreea-Ioana Vicas
Leeds Test Objects Ltd., UK	Mike Bannard (LTO Lead) Adrian Walker Steven Olley Rachel Lamb Pavel Nyvit
Katholieke Universiteit Leuven, Belgium	Reinhilde Jacobs (Senior scientist) Hilde Bosmans Ria Bogaerts Olivia Nackaerts Ruben Pauwels Bart Vandenberghe Guozhi Zhang Ali Algerban

Katholieke Universiteit Leuven, Belgium <i>(continued)</i>	Maria Eugenia Guerrero Jilke Beinsbergher Pisha Pittayapat
Malmö University, Sweden	Christina Lindh (Senior scientist) Madeleine Rohlin Mats Nilsson Helena Christell Mikael Jurman Maisa Warda Unal Oren
Vilnius University, Lithuania	Deimante Ivanauskaite (Senior scientist) Julius Ziliukas Ausra Urboniene

GUIDELINE DEVELOPMENT PANEL MEMBERS

NAME	CURRENT JOB TITLE	AFFILIATION
Dr Vivian Rushton*	Senior Lecturer/Honorary Consultant in Dental and Maxillofacial Radiology	University of Manchester, UK
Prof. Keith Horner	Professor of Oral and Maxillofacial Imaging/ Honorary Consultant in Dental and Maxillofacial Radiology	University of Manchester, UK
Dr. Anne-Marie Glenny	Senior Lecturer in Evidence Based Oral Health Care	University of Manchester, UK
Mrs. Anne Walker	Consultant Clinical Scientist (Group Leader, Diagnostic Radiology and Radiation Protection)	University of Manchester, UK and North Western Medical Physics, The Christie NHS Foundation Trust
Dr. Chrysoula Theodorakou	Postdoctoral Research Associate	University of Manchester, UK
Prof. Hugh Devlin	Professor of Restorative Dentistry	University of Manchester, UK
Prof. Kevin O'Brien	Professor of Orthodontics	University of Manchester, UK
Prof. Kostas Tsiklakis	Professor and Chairman of Oral Diagnosis and Radiology	National and Kapodistrian University of Athens, Greece
Prof. Kety Nicopolou-Karayianni	Professor of Oral Diagnosis and Radiology	National and Kapodistrian University of Athens, Greece
Dr. Anastasia Mitsea	Postdoctoral Research Associate Oral Diagnosis and Radiology	National and Kapodistrian University of Athens, Greece
Dr. Harry Stamatakis	Lecturer, Oral Diagnosis and Radiology Department	National and Kapodistrian University of Athens, Greece
Dr. Mihaela Hedesi	Primary radiology clinician, Head of Dental Radiology department	"Iuliu Hatieganu" University of Medicine and Pharmacy in Cluj-Napoca, Romania
Dr. Horatiu Rotaru	Oral and Maxillofacial Surgeon	"Iuliu Hatieganu" University of Medicine and Pharmacy in Cluj-Napoca, Romania
Dr. Cristian Dinu	Oral and Maxillofacial Surgeon	"Iuliu Hatieganu" University of Medicine and Pharmacy in Cluj-Napoca, Romania
Dr. Bogdan Crisan	Oral and Dentoalveolar Surgeon	"Iuliu Hatieganu" University of Medicine and Pharmacy in Cluj-Napoca, Romania
Dr. Bart Vandenberghe	Dentist and scientific researcher	Katholieke Universiteit Leuven, Belgium
Prof. Ria Bogaerts	Senior Physicist of Personnel Dosimetry and Professor in Health Physics	Katholieke Universiteit Leuven, Belgium
Prof. Hilde Bosmans	Head of the Radiology Physics Group and Professor in Medical Physics	Katholieke Universiteit Leuven, Belgium
Mr Ruben Pauwels	Postgraduate student	Katholieke Universiteit Leuven, Belgium
Prof. Christina Lindh	Professor of Oral and Maxillofacial Radiology and Certified Specialist in Oral and Maxillofacial Radiology	Malmö University, Sweden
Prof. Madeleine Rohlin	Professor of Odontological Diagnostics and Certified Specialist in Oral and Maxillofacial Radiology	Malmö University, Sweden
Ms. Deimante Ivanauskaite	Assistant of Institute of Odontology	Vilnius University, Lithuania
Dr. Gillian Armitt	SEDENTEXCT Project Manager	University of Manchester, UK

*Guideline Development Panel Lead

Thanks are also due to the entire SEDENTEXCT Project membership for their contributions and advice on this document.

ACKNOWLEDGMENTS

The SEDENTEXCT project (2008-2011) acknowledges the support of The Seventh Framework Programme of the European Atomic Energy Community (Euratom) for nuclear research and training activities (2007 to 2011).

We thank the following people for their direct assistance with the production of these guidelines:

- Helen McEvoy for library services.
- Gareth Hughes and Mohammed Islam for website services.
- Linda Norman for secretarial support.

We also thank the following individuals, external to the SEDENTEXCT project, who kindly agreed to review the drafts of this document and who provided valuable suggestions for improvement:

- Nicholas Drage
- Andrew Gulson
- John Holroyd
- John B Ludlow
- Ralf Schulze
- Stuart C White

FOREWORD

One objective of the SEDENTEXCT project has been to review the current literature on CBCT and to derive useful guidelines that will clarify those clinical situations in which this imaging technique would be found to be beneficial to both the clinician and the patient.

The method chosen was systematic review of the literature. The literature available for formal review was, however, limited in quantity. Because of this, the Guideline Development Panel also reviewed the many case reports/ series and non-systematic reviews available.

Of particular note is the proliferation in dental CBCT equipment manufacturers and models; **research evidence for one CBCT machine may not apply to other equipment**. As a consequence, caution is needed in generalising research findings. Many of the recommendations made are “Best Practice” rather than carrying any formal evidence grade, based upon the informed judgement of the Guideline Development Panel.

Please remember that the literature reviewed does not take complete account of publications in the three months prior to the development of these guidelines. In a rapidly developing research field such as this, it will be important that these Guidelines are reviewed in the future. This task would probably be most appropriately taken on by the European Academy of Dental and Maxillofacial Radiology, in conjunction with appropriate collaboration with medical physics experts and colleagues in other dental specialties.

Dr. Vivian E Rushton

*Senior Lecturer and Honorary Consultant in Dental and Maxillofacial Radiology
The University of Manchester, UK
SEDENTEXCT Work package 1 and Guideline Development Panel Lead*

1: INTRODUCTION AND GUIDELINE DEVELOPMENT

1.1 Imaging in dentistry and the dental and maxillofacial specialties

Radiology is essential to dentists for determining the presence and extent of disease in patients for whom a thorough patient history and examination has been performed. It also has roles in treatment planning, monitoring disease progression and in assessing treatment efficacy.

However, an integral part of radiology is exposure of patients and, potentially, clinical staff to X-rays. No exposure to X-rays can be considered completely free of risk, so the use of radiation by dentists is accompanied by a responsibility to ensure appropriate protection. Unlike most medical imaging, dentists use radiology to a relatively greater extent on children and young adults, so the need for judicious use is paramount.

The advent of CBCT has been an enormous advance in dental imaging. It is a type of imaging technology that is entirely new to dentists. All stakeholders have a responsibility to deliver this technology to patients in a responsible way, so that diagnostic value is maximised and radiation doses kept as low as reasonably achievable.

1.2 Guideline development

1.2.1 Aim

The aim of the work was to develop comprehensive, evidence-based guidelines on use of CBCT in dentistry, including referral criteria, quality assurance guidelines and optimisation strategies.

As well as providing recommendations on the use of dental CBCT in clinical practice, the intention was that the guidelines would be used to identify gaps in research. An over-arching research strategy would be developed to encourage the development of subsequent research projects which will be formative in the update of future evidence-based guidelines for the use of dental CBCT.

1.2.2 Methodology

Guideline development panel ("The Panel")

A multidisciplinary team was formed from the SEDENTEXCT project academic institutions, consisting of nationally and internationally recognised experts, including dentists, dental radiologists, medical physicists and other dental specialists, including oral and maxillofacial surgery, orthodontics, periodontology and restorative dentistry. The Panel membership was derived from colleagues attending the first SEDENTEXCT

meeting held in Leuven in January, 2008, and aimed to represent the many specialties that routinely work with dental CBCT. New members were added to the Panel during the course of the project where a gap in expertise was identified. No conflicts of interest were identified for any member of the Panel.

Guideline development process

The guidelines have been developed following the methods outlined by the Scottish Intercollegiate Guideline Network (SIGN, 2008). For certain questions addressed in the guidelines, however, the SIGN methods were not deemed applicable. Formal consensus methods were used to produce recommendations based on expert opinion where research evidence was lacking.

Provisional guidelines were developed in 2009 (SEDEXCT 2009). The guideline development process used in the current “Definitive Guideline” document was amended to take into account changes in methodology and feedback from the Panel.

The overall administration of the guidelines was shared by the SEDEXCT Work package 1 Lead and the Project Coordinator in Manchester, UK.

Scope of the guidelines

At the first meeting of the Panel a consensus process was used to identify the scope of the guidelines. The following key topic areas were initially identified:

- Diagnostic Accuracy Studies
- Dose and Risk
- Optimisation
- Quality standards/assurance
- Cost/Benefit Analysis
- CBCT use

Identification of the literature

An initial search of the FDI guideline database (www.fdiworldental.org) the National Guidelines Clearing House (www.guidelines.gov/index.asp) and MEDLINE (OVID) was undertaken to identify existing guidelines. In addition, searches for scientific papers on the identified topic areas were conducted using MEDLINE (OVID). An initial “scoping search” was undertaken to gain an overview of the volume of literature; identify further questions that may need to be addressed; establish the research methodologies used within each area and also to identify further search terms for refining the search strategy. There were no restrictions with regard to publication status or language of publication.

The Provisional Guidelines were published in 2009. The search used in the development of the provisional guidelines was modified to increase sensitivity. Box 1 shows the final search strategy used for MEDLINE (OVID). The following databases were searched up to October 2010:

MEDLINE (OVID) (1950 onwards)
 EMBASE (OVID) (1980 onwards)
 Web of Science
 Scopus
 UK Clinical Research Network
 Clinical Trials.gov
 Register of Controlled Trials (www.controlled-trials.com)
 NICE guidelines (www.nice.org.uk)
 FDI World Dental Federation Guidelines (www.fdiworldental.org).

Additional relevant studies published after this date and identified by other means were also included, although no formal searching was conducted after October 2010.

Box 1. Search strategy developed for MEDLINE (OVID)

1. cone beam computed tomography.mp.
2. volumetric radiography.mp.
3. volumetric tomography.mp.
4. digital volumetric tomography.mp.
5. digital volume tomography.mp.
6. Cone-beam.mp. or exp Cone-Beam Computed Tomography/
7. (volume ct or volumetric ct).mp.
8. (volume computed tomography or volumetric computed tomography).mp.
9. (cbct or qcbct).mp.
10. or/1-9
11. (dental or dentistry).mp.
12. exp dentistry/
13. (intra-oral or intraoral).mp. [title, original title, abstract, name of substance word, subject heading word]
14. oral surgery.mp. or exp surgery, oral/
15. endodontics\$.mp. or exp endodontics/
16. orthodontics\$.mp. or exp orthodontics/
17. (periodontic\$ or periodontology).mp. or exp periodontics/
18. exp dental caries/
19. maxillofacial.mp.
20. or/11-19
21. 10 and 20

In addition to the searches for published primary research, national guidelines were also searched for and used as source material (Box 2).

Assessment of relevance

All search results were imported into Endnote (version XI) for coding. The results of the searching were distributed for screening of titles and abstracts. This process was undertaken independently by teams of three members of the Panel. Full articles were

retrieved for all articles considered to be potentially relevant to the subject area by one or more of the reviewers.

Box 2. National guidelines used as source material

Advies van de Hoge Gezondheidsraad nr. 8705. Dentale Cone Beam Computed Tomography. Brussel: Hoge Gezondheidsraad, 2011. www.hgr-css.be

Haute Autorité de Santé. Tomographie Volumique a Faisceau Conique de la Face (Cone Beam Computerized Tomography). Rapport d'évaluation Technologique. Service évaluation des actes professionnels. Saint-Denis La Plaine: Haute Autorité de Santé, 2009. <http://www.has-sante.fr>

Health Protection Agency. Recommendations for the design of X-ray facilities and quality assurance of dental Cone Beam CT (Computed tomography) systems HPA-RPD-065 JR Holroyd and A Walker. Chilton: Health Protection Agency, 2010a.

Health Protection Agency. Guidance on the Safe Use of Dental Cone Beam CT (Computed Tomography) Equipment. HPA-CRCE-010. Chilton: Health Protection Agency, 2010b.

Leitlinie der DGZMK. Dentale Volumentomographie (DVT) - S1 Empfehlung. Deutsche Zahnärztliche Zeitschrift 64, 2009: 490 - 496.

Statens strålevern. Stråleverninfo 8:2010. Krav for bruk av Cone Beam CT ved odontologiske virksomheter. Østerås: Statens strålevern, 2010.

Sundhedsstyrelsen. Statens Institut for Strålebeskyttelse. Krav til 3D dental. Herlev: Statens Institut for Strålebeskyttelse, 2009.

Data extraction/quality assessment

The full paper copies of each article identified as being relevant (or potentially relevant) for inclusion in the guidelines were assessed independently and in duplicate and coded as into one or more of the following categories:

- Radiation dose and risk
- Justification for referral
- Equipment factors in the reduction of radiation risk to patients
- Quality standards/assurance
- Staff protection
- Economic evaluation
- CBCT uses*

(*it was noted that much evidence on dental CBCT comes from case-series and case-reports. In order to gain an understanding of how dental CBCT is being used in clinical practice, it was felt important to gather information from these studies and an assessment of them was undertaken by two Panel members using a proforma adapted from Ramulu et al (2005). However, whilst it was thought useful to identify and report these studies for illustrative purposes, no attempt was made to do a comprehensive review of them).

For all papers coded as “Justification for referral”, an assessment sheet was produced based on the relevant SIGN checklist and the QUADAS checklist (Whiting et al 2003). Studies were sub-divided into those that were diagnostic accuracy studies (primary focus), measurement accuracy or observer studies. Studies were also classified according to their clinical application (Box 3).

Box 3. Clinical categories used for papers coded as “Justification for referral”

- Localised applications of CBCT for the developing dentition
- Generalized application of CBCT for the developing dentition
- Dental caries diagnosis
- Periodontal assessment
- Assessment of periapical disease
- Endodontics
- Dental trauma
- Exodontia
- Implant dentistry
- Bony pathosis
- Facial trauma
- Orthognathic surgery
- Temporomandibular joint

For all other areas (apart from CBCT uses) a generic proforma was developed to tabulate the key features of the study and identify any potential weaknesses in study design.

During the assessment of the studies, each paper was coded as to study design and potential risk of bias (high risk of bias (-), moderate risk of bias (+), low risk of bias (++)). This information was used to aid the grading of any recommendations.

Production and grading of recommendations

The results of the assessment process were used to develop evidence tables. These tables were used to develop recommendations and identify gaps in the literature. Where research evidence was insufficient, the expertise of the Panel was used to draw up provisional “Good Practice” recommendations.

The Delphi technique was used to obtain a consensus from members of the European Academy of Dento-Maxillo-Facial Radiology (EADMFR) on the provisional “Good Practice” statements using an online survey technique. The provisional statements

were distributed electronically to all members of the aforementioned group, along with the draft guideline document. Participants were asked to grade each statement from 1 to 5 (strongly disagree to strongly agree). Space was provided for additional comments. The responses were collated and analysed. Consensus was achieved after the first survey round.

When producing recommendations consideration was given to:

- Volume of evidence
- Applicability of the findings to clinical practice
- Generalisability of the results presented to the guideline's target population
- Consistency of the results (highlight any major inconsistencies)
- Clinical impact (e.g resource implications, balance of risk/benefit)

Each provisional recommendation was linked, where applicable, to the relevant research evidence. It was graded according to an adaptation of the SIGN grading system (Tables 1 and 2).

Table 1.1: Grading systems used for levels of evidence [adapted from Scottish Intercollegiate Guidelines Network (SIGN), 2008].

1++	High quality meta-analyses/systematic reviews of randomised controlled trials (RCTs) or RCTs (including <i>in vitro</i> studies) with a very low risk of bias
1+	Well conducted meta-analyses/systematic review of RCTs, or RCTs (including <i>in vitro</i> studies) with moderate risk of bias
1-	Meta-analyses/ systematic reviews of RCTs, or RCTs (including <i>in vitro</i> studies) with high risk of bias
2++	High quality systematic reviews of case-control or cohort studies; High quality non-randomised trials, case-control or cohort studies with a very low risk of confounding, bias, or chance and high probability that the relationship is causal
2+	Well conducted non-randomised trials, case-control or cohort studies with a moderate risk of confounding, bias or chance and a moderate probability that the relationship is causal
2-	Non-randomised trials, case-control or cohort studies with a high risk of confounding, bias, or chance and a significant risk that the relationship is not causal
3	Non-analytic studies, e.g. case series, cross-sectional surveys
4	Expert opinion

Table 2: Grading systems used for levels of evidence [adapted from Scottish Intercollegiate Guidelines Network (SIGN), 2008].

Grade	
A	At least one meta analysis, systematic review, or RCT rated as 1++, and directly applicable to the target population; or a systematic review of RCTs or a body of evidence consisting principally of studies rated as 1+, directly applicable to the target population, and demonstrating overall consistency of results
B	A body of evidence including studies rated as 2++, directly applicable to the target population, and demonstrating overall consistency of results; or extrapolated evidence from studies rated as 1++ or 1+
C	A body of evidence including studies rated as 2+, directly applicable to the target population and demonstrating overall consistency of results; or extrapolated evidence from studies rated as 2++
D	Evidence level 3 or 4; or extrapolated evidence from studies rated as 2+
GP	Good Practice (based on clinical expertise of the guideline group and Consensus of stakeholders)

Two additional gradings are used in this document:

- A grade of “**ED**” is applied where a statement is directly derived from The Council of the European Union Directive 96/29/Euratom of 13 May 1996 (laying down basic safety standards for the protection of the health of workers and the general public against the dangers arising from ionizing radiation) or Council Directive 97/43/Euratom of 30 June 1997 (on health protection of individuals against the dangers of ionizing radiation in relation to medical exposure).
- A grade of “**BP**” is applied where a statement was identical to, or directly derived from, a “Basic Principle” of use of dental CBCT, as developed by consensus of the European Academy of Dental and Maxillofacial Radiology (see Section 3 of this document).

1.3 Future guideline review

No set of guidelines is permanent. In the context of a rapidly growing new technology like dental CBCT, the need for review and development is even more important. This is particularly needed for referral criteria. The first formal statement in this document is, therefore, to recommend that the Guidelines are reviewed after a period no longer than five years after its publication.

These Guidelines should be reviewed and renewed using an evidence-based methodology after a period no greater than five years after publication

GP

1.4 References

Ramulu VG, Levine RB, Hebert RS, Wright SM. Development of a case report review instrument. *J Clin Pract* 2005; 59: 457-461.

Scottish Intercollegiate Guidelines Network (SIGN). A guideline developers' handbook. Edinburgh: SIGN; Revised Edition January 2008. Report No: 50.

SEDENTEXCT Guideline Development Panel. Radiation Protection: Cone Beam CT for Dental and Maxillofacial Radiology Provisional Guidelines 2009 (v 1.1 May 2009). www.sedentexct.eu

Whiting P, Rutjes AWS, Reitsma JB, Bossuyt PB, Kleijnen J. The development of QUADAS: a tool for the quality assessment of studies of diagnostic accuracy included in systematic reviews. *BMC Medical Research Methodology* 2003, 3: 25.

2: RADIATION DOSE AND RISK

2.1: X-rays

X-rays are a type of electromagnetic (EM) radiation. EM radiation also includes visible light, radio waves, microwaves, cosmic radiation, and several other varieties of “rays”. All can be considered as “packets” of energy, called photons, which have wave properties, most importantly a wavelength and frequency. EM radiation can vary in wavelength from 10^{-13} to 10^3 m with X-rays having a small wavelength of 10^{-9} to 10^{-13} m. The importance of this is that small wavelengths mean high energy, deeper penetration through matter and high energy transfer to the matter. When X-rays hit atoms this energy can be transferred, producing ionisation of atoms. Other examples of ionising radiation are alpha, beta and gamma radiation, which are mostly associated with the decay of radioactive materials. All ionising radiations have the capability cause harm to the organs and tissues of the body of exposed persons.

2.2: Radiation damage

When patients undergo X-ray examinations, millions of photons pass through their bodies. These can damage any molecule by ionisation, but damage to the DNA in the chromosomes is of particular importance. Most DNA damage is repaired immediately, but rarely a portion of a chromosome may be permanently altered (a mutation). This may lead ultimately to the formation of a tumour. The latent period between exposure to X-rays and the clinical diagnosis of a tumour may be many years. The risk of a tumour being produced by a particular X-ray dose can be estimated; therefore, knowledge of the doses received by radiological techniques is important. While doses and risks for dental radiology are small, a number of epidemiological studies have provided some limited evidence of an increased risk of brain (Longstreth et al, 1993; Preston-Martin & White, 1990), salivary gland (Preston-Martin & White, 1990; Horn-Ross et al, 1997) and thyroid (Hallquist et al, 1994; Wingren et al, 1997; Memon et al, 2010) tumours for dental radiography.

The effects described above are believed to have no threshold radiation dose below which they will not occur (European Commission, 2001). They can be considered as “chance” (stochastic) effects, where the magnitude of the risk, though not the severity of the effect, is proportional to the radiation dose. There are other known damaging effects of radiation, such as cataract formation, skin erythema and effects on fertility, which definitely have threshold doses below which they will not occur. These threshold doses vary in size, but all are of a magnitude far greater than those given in dental radiography. Thus, except in extraordinary circumstances, these deterministic effects are given no further consideration.

2.3: Radiation dose

The terms “dose” and “exposure” are widely used but often misunderstood. “Doses” may be measured for particular tissues or organs (e.g. skin, eye, bone marrow) or for

the whole body, while “exposure” usually refers to equipment settings (time, mA, kV). A commonly used measure of dose in surveys is “entrance dose”, measured in milliGrays (mGy). This has an advantage of being fairly easily measured by placing dosimeters on the patient’s skin. Diagnostic reference levels (DRLs), based upon surveys of entrance dose or other easily measured quantities, may be set as standards against which X-ray equipment and their operation by clinicians can be assessed as part of quality assurance.

In these Guidelines, however, radiation dose is expressed as *effective dose*, measured in units of energy absorption per unit mass (joules / kg) called the Sievert (more usually the microSievert, μSv , representing one millionth of a Sievert). Effective dose is calculated for any X-ray technique by measuring the energy absorption in a number of “key” organs/tissues in the body. Each organ dose is multiplied by a weighting factor that has been determined as a reflection of its radiosensitivity. These weighted doses are added together, so that the final figure is a representation of “whole body” detriment. While effective dose is an impossible quantity to measure *in vivo*, it is possible to determine it from laboratory studies or computer modelling. This can then be used to estimate radiation risk. Effective dose permits a comparison of different types of examinations to different anatomical regions.

Many studies have measured doses of radiation for dental radiography, but only some have estimated effective dose. Much published work on conventional dental radiographic techniques pre-dates the recent revision of tissue weighting factors by the ICRP (ICRP 2007). This revision altered the existing tissue weighting factors and specific weighting factors were added for salivary glands, brain, gall/bladder, heart, lymphatic nodes, oral mucosa and prostate. As salivary glands, brain and oral mucosa are often irradiated during dental X-ray examinations, this means that studies using old weighting factors will very likely give different results to those using the new factors. Furthermore, variation in the technical parameters of the X-ray equipment and image receptors used in studies means that care should be taken when comparing dose estimations from different studies. Because it is a relatively new technique, most dental CBCT dosimetry research has used the more recent tissue weighting factors. Nonetheless, it is still important to recognise that the doses reported for one dental CBCT machine may be quite different to another and that ranges of dose are more appropriate to use than absolute figures.

2.4: Radiation risk

Radiation detriment can be considered as the total harm experienced by an irradiated individual. In terms of stochastic effects, this includes the detriment-adjusted nominal risk of cancer and heritable effects. The detriment-adjusted risk factor for the whole population is $5.7 \times 10^{-2} \text{ Sv}^{-1}$. Regarding cancer, radiation detriment considers cancer incidence weighted for lethality and life impairment. Table 2.1 was taken from ICRP (2007) and it gives the breakdown of this summed figure into its constituent elements. Heritable effects are believed to be negligible in dental radiography (White 1992) and this is also true for dental CBCT.

Risk is age-dependent, being highest for the young and least for the elderly. Here, risks are given for the adult patient at 30 years of age. These should be modified using

the multiplication factors given in Table 2.2 (derived from ICRP 1990). These represent averages for the two sexes; at all ages risks for females are slightly higher and those for males slightly lower.

Beyond 80 years of age, the risk becomes negligible because the latent period between X-ray exposure and the clinical presentation of a tumour will probably exceed the life span of a patient. In contrast, the tissues of younger people are more radiosensitive and their prospective life span is likely to exceed the latent period.

Table 2.1: Detriment-adjusted nominal risk coefficients for stochastic effects

Detriment (10^{-2}Sv^{-1})	
Cancer	5.5
Hereditary effects	0.2
Total	5.7

Table 2.2: Risk in relation to age. These data are derived from (ICRP 1990) and represent relative attributable lifetime risk based upon a relative risk of 1 at age 30 (population average risk). It assumes the multiplicative risk projection model, averaged for the two sexes. In fact, risk for females is always relatively higher than for males.

Age group (years)	Multiplication factor for risk
<10	x 3
10-20	x 2
20-30	x 1.5
30-50	x 0.5
50-80	x 0.3
80+	Negligible risk

2.5: Doses and risks with CBCT

The literature review conducted by the SEDENTEXCT project included 13 studies in which dosimetry for dental CBCT was performed and in which effective dose was calculated either using the ICRP (2007) tissue weighting factors or using the ICRP (1990) tissue weighting factors with the radiosensitivity of the salivary glands and brain taken into account. Two further studies from the SEDENTEXCT Consortium were also included (Pauwels et al, *in press*; Theodorakou et al, *in press*). Table 2.3a shows the reported effective doses for a range of dental CBCT units collated from the studies reviewed, all of which used “adult” phantoms. Table 2.3b provides equivalent data

using paediatric phantoms conducted as part of the SEDENTEXCT project by Theodorakou et al (*in press*). The more restricted dose range seen for paediatric phantom studies reflects the relatively limited range of equipment studied by Theodorakou et al (*in press*) and the exclusion of the higher dose equipment included in Table 2.3a.

Pauwels et al (*in press*) presented data on average relative contribution of organ doses to effective dose in dental CBCT (Fig.2.1). The bulk of the contribution comes from remainder organs, salivary glands, thyroid gland and red bone marrow. For the paediatric phantom, the remainder organs, the salivary glands and the thyroid contribute equally and for the adolescent phantom the remainder organs and the salivary glands gave the highest contribution (Theodorakou et al, *in press*).

Fig 2.1: Average contribution of organ doses to effective dose calculations for CBCT, adapted from Pauwels et al (in press).

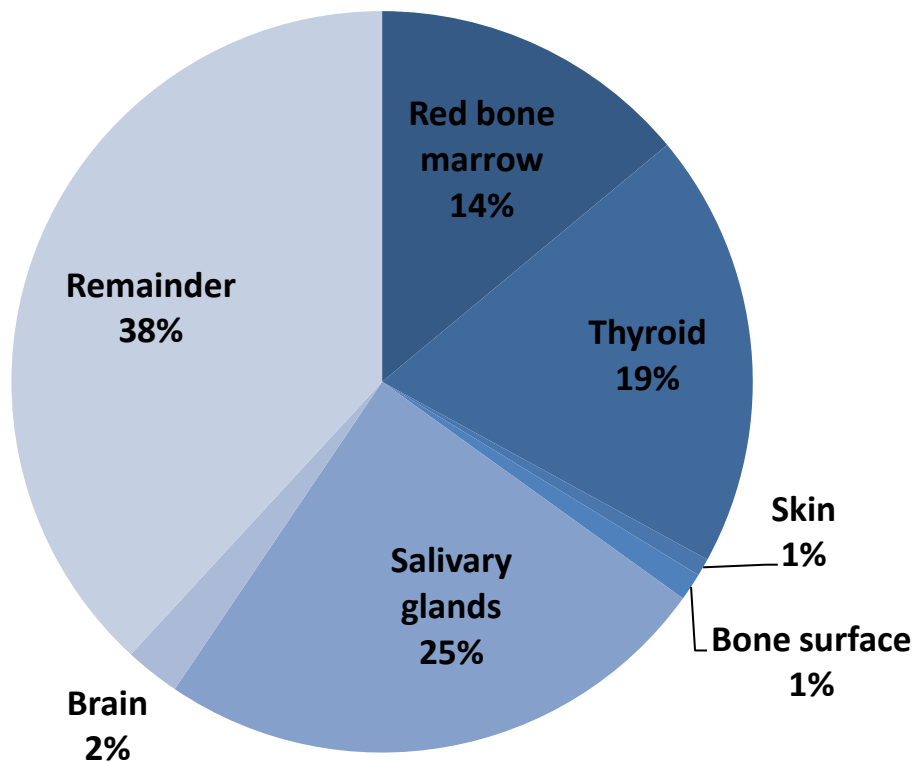


Table 2.3c presents the reported effective doses for conventional imaging and multislice CT (MSCT) imaging to act as a comparison with dental CBCT data. The majority of studies were based on thermoluminescent dosimetry (TLD) techniques using anthropomorphic phantoms. They showed significant variation in methodology, especially with respect to the type of phantom used and TLD number and positioning. The effect of the number and position of the TLD dosimeters on the accuracy of the assessment has been assessed in the SEDENTEXCT project by Pauwels et al (*in press*). They recalculated their organ dose data using a limited number of selected TLDs and found significant variability in organ dose depending on the number and

position of TLDs, with the largest deviations seen for small FOV protocols and for thyroid and remainder tissues. This emphasises the importance of using sufficient TLDs in effective dose calculation for dental CBCT.

Looking at the median values and the ranges for dento-alveolar and craniofacial dental CBCT effective dose in Tables 2.3a and 2.3b, the reported data are markedly skewed, with high doses being reported in a small number of studies for particular equipment. What is suggested from this is that some dental CBCT equipment is associated with effective doses that are not as low as reasonably achievable.

Table 2.3a: The range of effective dose and the median values in parentheses from dental CBCT in μSv . Studies are divided into “dento-alveolar” (small and medium FOV) and “craniofacial” (large FOV). The height of the dento-alveolar FOVs is smaller than 10cm allowing imaging of the lower and upper jaws. For the craniofacial FOVs, the height is greater than 10cm allowing maxillofacial imaging.

Dental CBCT unit type	Effective dose (μSv)	References
Dento-alveolar	11-674 (61)	Ludlow et al 2003 Ludlow and Ivanovic 2008 Lofthag-Hansen et al 2008 Hirsch et al 2008 Okano et al 2009 Loubele et al 2009 Roberts et al 2009 Suomalainen et al 2009 Qu et al 2010 Pauwels et al, in press
Craniofacial	30-1073 (87)	Ludlow et al 2003 Tsiklakis et al 2005 Ludlow et al 2006 Ludlow and Ivanovic 2008 Garcia Silva et al 2008a Okano et al 2009 Faccioli et al 2009 Loubele et al 2009 Roberts et al 2009 Pauwels et al, in press

Table 2.3b: The range of effective dose and the median values in parentheses from dental CBCT in μSv for paediatric phantoms. Studies are divided into “dento-alveolar” (small and medium FOV) and “craniofacial” (large FOV).

Age	Dental CBCT unit type	Effective dose (μSv)	Reference
10 year-old phantom	Dento-alveolar	16-214 (43)	Theodorakou et al (in press)
	Craniofacial	114-282 (186)	
Adolescent phantom	Dento-alveolar	18-70 (32)	
	Craniofacial	81-216 (135)	

Table 2.3c: Effective dose from conventional dental imaging techniques in μSv . MSCT = multislice CT.

	Effective dose (μSv)	References
Intraoral radiograph	<1.5*	Ludlow et al 2008
Panoramic radiograph	2.7 – 24.3	Ludlow et al 2008 Okano et al 2009 Garcia Silva et al 2008b Palomo et al 2008 Garcia Silva et al 2008a
Cephalometric radiograph	<6	Ludlow et al 2008
MSCT maxillo-mandibular	280 - 1410	Okano et al 2009 Garcia Silva et al 2008a Loubele et al 2005 Faccioli et al 2009 Suomalainen et al 2009

*Figure for single intraoral radiograph calculated from data for 18 image full mouth intraoral survey and 4 image bitewing examination, both using a photostimulable phosphor plate or F-speed film with rectangular collimation. Substitution of round collimation increased this figure by almost five times, while slower film speeds increased the effective dose still further (Ludlow et al, 2008)

In summary, the radiation doses (and hence risks) from dental CBCT are generally higher than conventional dental radiography (intraoral and panoramic) but lower than MSCT scans of the dental area. Dose is dependent on equipment type and exposure settings, especially the field of view selected. In particular, “low dose” protocols on modern MSCT equipment may bring doses down significantly (Loubele et al 2005; Ballanti et al 2008).

Effective dose measurements of equipment reported here become dated very quickly, not least by new equipment manufacturers appearing. Indeed, some of the studies reviewed include dental CBCT equipment which has already been superseded by newer models, although it is likely that existing equipment will remain in clinical use for some years. As a method of overcoming this problem of maintaining current and valid data on dental CBCT doses, computed dose simulations offer considerable advantages. Work in the SEDENTEXCT project has been performed using Monte Carlo modelling of computational phantoms for a range of dental CBCT machines and imaging protocols. This facilitates estimation of effective dose of dental CBCT without the need for repeated dosimetry work on anthropomorphic phantoms.

2.6: References

Ballanti F, Lione R, Fiaschetti V, Fanucci E, Cozza P. Low-dose CT protocol for orthodontic diagnosis. *Eur J Paediatr Dent.* 2008; 9: 65-70.

European Commission. Radiation Protection 125: Low dose ionizing radiation and cancer risk. 2001. Office for Official Publications of the EC: Luxembourg.
<http://europa.eu.int/comm/environment/radprot/publications>.

European Commission. Radiation Protection 136. European Guidelines on Radiation Protection in Dental Radiology. Luxembourg: Office for Official Publications of the European Communities, 2004. Available from: http://ec.europa.eu/energy/nuclear/radioprotection/publication/doc/136_en.pdf

European Commission. Radiation Protection 88. Recommendations for the implementation of Title VII of the European Basic Safety Standards (BSS) Directive concerning significant increase in exposure due to natural radiation sources. 1997. Office for Official Publications of the EC: Luxembourg.

Faccioli N, M Barillari, S Guariglia, E Zivelonghi, A Rizzotti, R Cerini, et al., Radiation dose saving through the use of cone-beam CT in hearing-impaired patients. *Radiologia Medica*, 2009; 114: 1308-1318.

Garcia Silva MA, Wolf U, Heinicke F, Bumann A, Visser H, Hirsch E. Cone-beam computed tomography for routine orthodontic treatment planning: a radiation dose evaluation. *Am J Orthod Dentofacial Orthop* 2008a; 133: 640.e1-5.

Garcia Silva MA, Wolf U, Heinicke F, Gründler K, Visser H, Hirsch E. Effective dosages for recording Veraviewepocs dental panoramic images: analog film, digital, and panoramic scout for CBCT. *Oral Surg Oral Med Oral Pathol Oral Radiol Endod.* 2008b;106:571-7
106: 571-577.

Hallquist A, Hardell L, Degerman A, Wingren G, Boquist L. Medical diagnostic and therapeutic ionizing radiation and the risk for thyroid cancer: a case-control study. *Eur J Cancer Prevention* 1994; 3: 259-267.

Hirsch E, Wolf U, Heinicke F, Silva MA. Dosimetry of the cone beam computed tomography Veraviewepocs 3D compared with the 3D Accuitomo in different fields of view. *Dentomaxillofac Radiol* 2008; 37: 268-273.

Horn-Ross PL, Ljung BM, Morrow M. Environmental factors and the risk of salivary gland cancer. *Epidemiology* 1997; 8: 414-419.

ICRP Publication 103. The 2007 Recommendations of the International Commission on Radiological Protection. 2007. *Annals of the ICRP*: 37.

ICRP Publication 60. Recommendations of the International Commission on Radiological Protection. 1990. *Annals of the ICRP*: 21.

Lofthag-Hansen S, Thilander-Klang A, Ekestubbe A, Helmrot E, Gröndahl K. Calculating effective dose on a cone beam computed tomography device: 3D Accuitomo and 3D Accuitomo FPD. *Dentomaxillofac Radiol* 2008; 37: 72-79

Longstreth WT, Dennis LK, McGuire VM, Drangsholt MT, Koepsell TD. Epidemiology of intracranial meningioma. *Cancer* 1993; 72: 639-648.

Loubele M, Bogaerts R, Van Dijck E, Pauwels R, Vanheusden S, Suetens P, Marchal G, Sanderink G, Jacobs R. Comparison between effective radiation dose of CBCT and MSCT scanners for dentomaxillofacial applications. *Eur J Radiol* 2009; 71: 461-468.

Loubele M, Jacobs R, Maes F, Schutyser F, Debaveye D, Bogaerts R, Coudyzer W, Vandermeulen D, van Cleynenbreugel J, Marchal G, Suetens P. Radiation dose vs. image quality for low-dose CT protocols of the head for maxillofacial surgery and oral implant planning. *Radiat Prot Dosimetry* 2005; 117: 211-216.

- Ludlow JB, Davies-Ludlow LE, Brooks SL, Howerton WB. Dosimetry of 3 CBCT devices for oral and maxillofacial radiology: CB Mercuray, NewTom 3G and i-CAT. *Dentomaxillofac Radiol* 2006; 35: 219-26.
- Ludlow JB, Davies-Ludlow LE, Brooks SL. Dosimetry of two extraoral direct digital imaging devices: NewTom cone beam CT and Orthophos Plus DS panoramic unit. *Dentomaxillofac Radiol* 2003; 32: 229-234.
- Ludlow JB, Davies-Ludlow LE, White SC. Patient risk related to common dental radiographic examinations: the impact of 2007 International Commission on Radiological Protection recommendations regarding dose calculation. *J Am Dent Assoc.* 2008; 139: 1237-1243.
- Ludlow JB, Ivanovic M. Comparative dosimetry of dental CBCT devices and 64-slice CT for oral and maxillofacial radiology. *Oral Surg Oral Med Oral Pathol Oral Radiol Endod* 2008; 106: 106-114.
- Memon A, Godward S, Williams D, Siddique I, Al-Saleh K. Dental x-rays and the risk of thyroid cancer: a case-control study. *Acta Oncol.* 2010; 49: 447-453.
- Okano T, Harata Y, Sugihara Y, Sakaino R, Tsuchida R, Iwai K, Seki K, Araki K. Absorbed and effective doses from cone beam volumetric imaging for implant planning. *Dentomaxillofac Radiol* 2009; 38: 79-85.
- Palomo JM, Rao PS, Hans MG. Influence of CBCT exposure conditions on radiation dose. *Oral Surg Oral Med Oral Pathol Oral Radiol Endod* 2008; 105: 773-82.
- Pauwels R, Beinsberger J, Collaert B, Theodorakou C, Rogers J, Walker A, Cockmartin L, Bosmans H, Jacobs R, Bogaerts R, Horner K; The SEDENTEXCT Project Consortium. Effective dose range for dental cone beam computed tomography scanners. *Eur J Radiol* (in press).
- Preston-Martin S, White SC. Brain and salivary gland tumors related to prior dental radiography: implications for current practice. *J Am Dent Assoc* 1990; 120: 151-158.
- Qu XM, Li G, Ludlow JB, Zhang ZY, Ma XC. Effective radiation dose of ProMax 3D cone-beam computerized tomography scanner with different dental protocols. *Oral Surg Oral Med Oral Pathol Oral Radiol Endod.* 2010; 110:770-6.
- Roberts JA, Drage NA, Davies J, Thomas DW. Effective dose from cone beam CT examinations in dentistry. *Br J Radiol* 2009; 82: 35-40.
- Suomalainen A, Kiljunen T, Kaser Y, Peltola J, Kortetniemi M, Dosimetry and image quality of four dental cone beam computed tomography scanners compared with multislice computed tomography scanners. *Dentomaxillofac Radiol* 2009; 38: 367-378.
- Theodorakou C, Walker A, Horner K, Pauwels R, Bogaerts R, Jacobs R, The SEDENTEXCT Project Consortium. Estimation of paediatric organ and effective doses from dental cone beam computed tomography using anthropomorphic phantoms. *Br J Radiol* (in press).
- Tsiklakis K, Donta C, Gavala S, Karayiannic K, Kamenopoulou V, Hourdakis CJ, Dose reduction in maxillofacial imaging using low dose Cone Beam CT. *Eur J Radiol* 2005; 56: 413-417.
- White SC. Assessment of radiation risk from dental radiography. *Dentomaxillofac Radiol* 1992; 21: 118-126.
- Wingren G, Hallquist A, Hardell L. Diagnostic X-ray exposure and female papillary thyroid cancer: a pooled analysis of two Swedish studies. *Eur J Cancer Prevention* 1997; 6: 550-556.

3: BASIC PRINCIPLES

3.1: Background

The SEDENTEXCT project aimed to acquire key information necessary for sound and scientifically based clinical use of dental Cone Beam Computed Tomography (CBCT). As part of this aim, the project set an objective of developing evidence-based guidelines for dental and maxillofacial use of CBCT. Early in 2008, it became apparent that there was an urgent need to provide some basic guidance to users of dental CBCT because of concerns over inappropriate use. These concerns were voiced by the European Academy of DentoMaxilloFacial Radiology (EADMFR), an organisation whose objective is to promote, advance and improve clinical practice, education and/or research specifically related to the specialty of dental and maxillofacial radiology within Europe, and to provide a forum for discussion, communication and the professional advancement of its members. EADMFR has a membership exceeding 300 individuals whose special interest is imaging of the dental and maxillofacial region. It is multi-disciplinary, including dental radiologists, medical physicists, radiographers and scientists. It includes both academics (teachers and researchers) and clinicians. In view of the mutual aims of EADMFR and SEDENTEXCT, a decision was taken to collaborate in the development of a set of “Basic Principles” for the use of dental CBCT, based upon existing standards. These standards include fundamental international principles, EU Directives (Council of European Union, 1996, 1997) and previous Guidelines (European Commission 2004).

3.2: Methodology

The detailed methodology followed in the preparation of these guidelines is fully described elsewhere (Horner et al 2009). Briefly, a Guideline Development Panel was formed to develop a set of draft statements using existing EU Directives and Guidelines on Radiation Protection. The draft statements covered Justification, Optimisation and Training of dental CBCT users. These statements were revised after an open debate of attendees at the 11th EADMFR Congress on 28th June 2008. A modified Delphi procedure was then used to present the revised statements to the EADMFR membership, utilising an online survey in October/November 2008. Consensus of EADMFR members, indicated by high level of agreement for all statements, was achieved without a need for further rounds of the Delphi process.

A set of 20 “Basic Principles” on the use of dental CBCT were thus established. These act as core standards for EADMFR and are central to this Guideline publication.

3.3: The “Basic Principles”

1	CBCT examinations must not be carried out unless a history and clinical examination have been performed
2	CBCT examinations must be justified for each patient to demonstrate that the benefits outweigh the risks
3	CBCT examinations should potentially add new information to aid the patient’s management
4	CBCT should not be repeated ‘routinely’ on a patient without a new risk/benefit assessment having been performed
5	When accepting referrals from other dentists for CBCT examinations, the referring dentist must supply sufficient clinical information (results of a history and examination) to allow the CBCT Practitioner to perform the Justification process
6	CBCT should only be used when the question for which imaging is required cannot be answered adequately by lower dose conventional (traditional) radiography
7	CBCT images must undergo a thorough clinical evaluation (‘radiological report’) of the entire image dataset
8	Where it is likely that evaluation of soft tissues will be required as part of the patient’s radiological assessment, the appropriate imaging should be conventional medical CT or MR, rather than CBCT
9	CBCT equipment should offer a choice of volume sizes and examinations must use the smallest that is compatible with the clinical situation if this provides less radiation dose to the patient
10	Where CBCT equipment offers a choice of resolution, the resolution compatible with adequate diagnosis and the lowest achievable dose should be used
11	A quality assurance programme must be established and implemented for each CBCT facility, including equipment, techniques and quality control procedures
12	Aids to accurate positioning (light beam markers) must always be used
13	All new installations of CBCT equipment should undergo a critical examination and detailed acceptance tests before use to ensure that radiation protection for staff, members of the public and patient are optimal
14	CBCT equipment should undergo regular routine tests to ensure that radiation protection, for both practice/facility users and patients, has not significantly deteriorated
15	For staff protection from CBCT equipment, the guidelines detailed in Section 6 of the European Commission document ‘ <i>Radiation Protection 136. European Guidelines on Radiation Protection in Dental Radiology</i> ’ should be followed
16	All those involved with CBCT must have received adequate theoretical and practical training for the purpose of radiological practices and relevant competence in radiation protection
17	Continuing education and training after qualification are required, particularly when new CBCT equipment or techniques are adopted
18	Dentists responsible for CBCT facilities who have not previously received ‘adequate theoretical and practical training’ should undergo a period of additional theoretical and practical training that has been validated by an academic institution (University or equivalent). Where national specialist qualifications in DMFR exist, the design and delivery of CBCT training programmes should involve a DMF Radiologist
19	For dento-alveolar CBCT images of the teeth, their supporting structures, the mandible and the maxilla up to the floor of the nose (eg 8cm x 8cm or smaller fields of view), clinical evaluation (‘ <i>radiological report</i> ’) should be made by a specially trained DMF Radiologist or, where this is impracticable, an adequately trained general dental practitioner
20	For non-dento-alveolar small fields of view (e.g. temporal bone) and all craniofacial CBCT images (fields of view extending beyond the teeth, their supporting structures, the mandible, including the TMJ, and the maxilla up to the floor of the nose), clinical evaluation (‘ <i>radiological report</i> ’) should be made by a specially trained DMF Radiologist or by a Clinical Radiologist (Medical Radiologist)

3.4: References

Council of the European Union. Council Directive 96/29/Euratom of 13 May 1996 laying down basic safety standards for the protection of the health of workers and the general public against the dangers arising from ionizing radiation. Official Journal of the European Communities N° L 159, 1996. Available from: http://ec.europa.eu/energy/nuclear/radioprotection/doc/legislation/9629_en.pdf

Council of the European Union. Council Directive 97/43/Euratom of 30 June 1997 on health protection of individuals against the dangers of ionizing radiation in relation to medical exposure, and repealing Directive 84/466/Euratom. Available from: http://ec.europa.eu/energy/nuclear/radioprotection/doc/legislation/9743_en.pdf

European Commission. Radiation Protection 136. European Guidelines on Radiation Protection in Dental Radiology. Luxembourg: Office for Official Publications of the European Communities, 2004. Available from: http://ec.europa.eu/energy/nuclear/radioprotection/publication/doc/136_en.pdf

Horner K, Islam M, Flygare L, Tsiklakis T, Whaites E. Basic Principles for Use of Dental Cone Beam CT: Consensus Guidelines of the European Academy of Dental and Maxillofacial Radiology. Dentomaxillofac Radiol. 2009; 38: 187-195.

4: JUSTIFICATION AND REFERRAL CRITERIA

4.1: Introduction

As with any X-ray exposure, CBCT entails a risk to the patient. It is essential that any X-ray examination should show a net potential benefit to the patient, weighing the total potential diagnostic benefits it produces against the individual detriment that the exposure might cause. The efficacy, benefits and risk of available alternative techniques having the same objective but involving less (or no) exposure to X-rays should be taken into account. A record of the justification process must be made in the patient's clinical records.

All CBCT examinations must be justified on an individual basis by demonstrating that the potential benefits to the patients outweigh the potential risks. CBCT examinations should potentially add new information to aid the patient's management. A record of the Justification process must be maintained for each patient

ED BP

In order that the justification process can be carried out, it is essential that selection of dental CBCT is based on the individual patient's history and a clinical examination. The "routine" use of dental CBCT on patients based on a generalised approach rather than individual prescription is unacceptable. A "routine" (or "screening") examination is defined as one in which a radiograph is taken regardless of the presence or absence of clinical signs and symptoms.

CBCT should not be selected unless a history and clinical examination have been performed. "Routine" or "screening" imaging is unacceptable practice

ED BP

Choosing dental CBCT for a patient should also be based upon consideration of the prevalence of diseases, their rates of progression and the diagnostic accuracy of CBCT, compared with traditional techniques, for the application in question.

"Diagnostic efficacy" of any medical imaging modality encompasses a spectrum of performance measures. The hierarchical model presented by Fryback & Thornbury (1991) conceptualised this into six levels of efficacy:

- *Technical efficacy*
- *Diagnostic accuracy efficacy*
- *Diagnostic thinking efficacy*
- *Therapeutic efficacy*
- *Patient outcome efficacy*
- *Societal efficacy*

In reviewing the literature on dental CBCT, the Panel recognised that understanding of its diagnostic efficacy was largely limited to the first two of these levels. Even for these, knowledge is incomplete. Only a few publications were identified which address higher levels of diagnostic efficacy. This means that the development of guidelines with high evidence grades was precluded. It also highlights the need for clinical trials which will provide information on “higher level” efficacies, notably Patient Outcome Efficacy (e.g. the proportion of patients improved in a clinical therapeutic procedure with the use of CBCT compared with the proportion improved without CBCT).

Consulting guidelines facilitates the process of selecting radiographs. Such guidelines, called “referral criteria” or “selection criteria” exist for both medical and traditional dental imaging. Radiographic referral criteria have been defined as:

“descriptions of clinical conditions derived from patient signs, symptoms and history that identify patients who are likely to benefit from a particular radiographic technique”.

As with any guideline, these are not intended to be rigid constraints on clinical practice, but a concept of good practice against which the needs of the individual patient can be considered. The term “referral criteria” is appropriate for medical practitioners, where radiography is usually arranged by referral to a specialist in radiology. With CBCT, this situation may also apply, with the dentist referring to a hospital department or to a dentist-colleague. When acting as a referrer, the dentist should ensure that adequate clinical information about the patient is provided to the person taking responsibility for the exposure.

When referring a patient for a CBCT examination, the referring dentist must supply sufficient clinical information (results of a history and examination) to allow the CBCT Practitioner to perform the Justification process

ED BP

In the Provisional Guideline document (SEDENTEXCT 2009), referral criteria were devised for a range of uses of dental CBCT that became apparent during the course of the systematic review, with priority given to paediatric uses. In the interim period, before publication of this current document, some European national organizations have presented indications for the use of dental CBCT (Haute Autorité de Santé, 2009; Leitlinie der DGZMK, 2009; Advies van de Hoge Gezondheidsraad, 2011); due account has been taken of these.

4.1.1 Dimensional accuracy of CBCT

One aspect of imaging which is important to all aspects of clinical use of dental CBCT is dimensional (geometric) accuracy. Clearly, however, this is of particular importance in certain applications, such as implantology and orthodontics where accurate quantitative information is required. There are numerous publications on linear accuracy of dental CBCT and some dealing with angular measurements. Although these fell outside the strict inclusion criteria of the systematic review of diagnostic accuracy, the Panel conducted a separate review process for these studies. While the search methodology for this element of the review may have omitted some research of relevance, the Panel identified 50 publications where the primary focus of studies was judged to be aspects of measurement accuracy (Agbaje et al 2007; Al-Ekrish et al 2011; Al-Rawi et al 2010; Ballrick et al 2008; Baumgaertel et al 2009; Berco et al 2009; Brown et al 2009; Cattaneo et al 2008; Cevidanes et al 2005; Chen et al 2008; Damstra et al 2010; Eggers et al 2008; Eggers et al 2009; Fatemitabar et al 2010; Fourie et al 2010; Grauer et al 2010; Gribel et al. 2011; Hassan et al. 2009; Hilgers et al 2005; Kamburoğlu et al. 2010; Kobayashi et al 2004; Kumar et al 2007; Kumar et al 2008; Lagravère et al. 2008; Lamichane et al 2009; Lascala et al 2004; Liu et al 2010; Loubele et al 2008; Ludlow et al 2007; Luk et al 2011; Lund et al 2009; Marmulla et al 2005; Mischkowski et al 2007; Moerenhout et al 2009; Moreira et al. 2009; Moshiri et al 2007; Naitoh et al 2009; Peck et al 2006; Periago et al 2008; Pinsky et al 2006; Razavi et al 2010; Sakabe et al 2007; Sherrard et al 2010; Stratemann et al 2008; Suomalainen et al 2008; Tsutsumi et al 2011; Van Assche et al 2007; Van Elsende et al 2010; van Vlijmen et al 2009; Veyre-Goulet et al 2008).

These studies encompassed a good range of dental CBCT equipment manufacturers and models. The results suggest that differences between CBCT-derived measurements and the reference standard appear to be small and are unlikely to be clinically significant. Laboratory studies do not, however, take account of minor patient movements which, while difficult to perceive in terms of poorer image quality, might contribute to added discrepancy between the image dimensions and reality. The methodologies and the objectives of these studies were usually very different, so that it remains difficult to make valid comparisons between equipment. Clearly, as new equipment is introduced, these kinds of efficacy studies should continue to be performed. It would, however, be valuable if a standard battery of tests using a commercially available phantom were prospectively adopted so that comparisons of equipment could be most usefully made.

4.1.2 References

Advies van de Hoge Gezondheidsraad nr. 8705. Dentale Cone Beam Computed Tomography. Brussel: Hoge Gezondheidsraad, 2011. www.hgr-css.be

Agbaje JO, Jacobs R, Maes F, Michiels K, van Steenberghe D. Volumetric analysis of extraction sockets using cone beam computed tomography: a pilot study on ex vivo jaw bone. *J Clin Periodontol* 2007; 34: 985-990.

Al-Ekrish AA, Ekram M. A comparative study of the accuracy and reliability of multidetector computed tomography and cone beam computed tomography in the assessment of dental implant site dimensions. *Dentomaxillofac Radiol.* 2011; 40: 67-75.

- Al-Rawi B, Hassan B, Vandenberghe B, Jacobs R. Accuracy assessment of three-dimensional surface reconstructions of teeth from cone beam computed tomography scans. *J Oral Rehabil.* 2010; 37: 352-358.
- Ballrick JW, Palomo JM, Ruch E, Amberman BD, Hans MG. Image distortion and spatial resolution of a commercially available cone-beam computed tomography machine. *Am J Orthod Dentofacial Orthop* 2008; 134: 573-582.
- Baumgaertel S, Palomo JM, Palomo L, Hans MG. Reliability and accuracy of cone-beam computed tomography dental measurements. *Am J Orthod Dentofacial Orthop* 2009; 136: 19-25; discussion 25-28.
- Berco M, Rigali PH Jr, Miner RM, DeLuca S, Anderson NK, Will LA. Accuracy and reliability of linear cephalometric measurements from cone-beam computed tomography scans of a dry human skull. *Am J Orthod Dentofacial Orthop.* 2009; 136: 17.e1-9; discussion 17-8.
- Brown AA, Scarfe WC, Scheetz JP, Silveira AM, Farman AG. Linear accuracy of cone beam CT derived 3D images. *Angle Orthod.* 2009 Jan;79(1):150-7.
- Cattaneo PM, Bloch CB, Calmar D, Hjortshoj M, Melsen B. Comparison between conventional and cone-beam computed tomography-generated cephalograms. *Am J Orthod Dentofacial Orthop* 2008; 134: 798-802.
- Cevidanes LHS, Bailey LJ, Tucker GR, Jr., Styner MA, Mol A, Phillips CL, Proffit WR, Turvey T. Superimposition of 3D cone-beam CT models of orthognathic surgery patients. *Dentomaxillofac Radiol* 2005; 34: 369-375.
- Chen L-C, Lundgren T, Hallstrom H, Cherel F. Comparison of different methods of assessing alveolar ridge dimensions prior to dental implant placement. *J Periodontol* 2008; 79: 401-405.
- Damstra J, Fourie Z, Huddleston Slater JJR, Ren Y. Accuracy of linear measurements from cone-beam computed tomography-derived surface models of different voxel sizes. *Am J Orthod Dentofacial Orthop* 2010; 137: 16.e1-6; discussion 16-17.
- Eggers G, Klein J, Welzel T, Muhling J. Geometric accuracy of digital volume tomography and conventional computed tomography. *Br J Oral Maxillofac Surg* 2008; 46: 639-644.
- Eggers G, Senoo H, Kane G, Muhling J. The accuracy of image guided surgery based on cone beam computer tomography image data. *Oral Surg Oral Med Oral Pathol Oral Radiol Endod* 2009; 107: e41-48.
- Fatemitabar SA, Nikgoo A. Multichannel computed tomography versus cone-beam computed tomography: linear accuracy of in vitro measurements of the maxilla for implant placement. *Int J Oral Maxillofac Implants.* 2010 May-Jun;25(3):499-505.
- Fourie Z, Damstra J, Gerrits PO, Ren Y. Evaluation of anthropometric accuracy and reliability using different three-dimensional scanning systems. *Forensic Sci Int* 2010; Oct 14. [Epub ahead of print]
- Fryback DG, Thornbury JR. The efficacy of diagnostic imaging. *Med Decis Making* 1991; 11: 88-94.
- Grauer D, Cevidanes LSH, Styner MA, Heulfe I, Harmon ET, Zhu H, Proffit WR. Accuracy and landmark error calculation using cone-beam computed tomography-generated cephalograms. *Angle Orthod* 2010; 80: 286-294.
- Gribel BF, Gribel MN, Manzi FR, Brooks SL, McNamara JA Jr. Accuracy and reliability of craniometric measurements on lateral cephalometry and 3D measurements on CBCT scans. *Angle Orthod.* 2011; 81: 3-10.

Haute Autorité de Santé. Tomographie Volumique a Faisceau Conique de la Face (Cone Beam Computerized Tomography). Rapport d'évaluation Technologique. Service évaluation des actes professionnels. Saint-Denis La Plaine: Haute Autorité de Santé, 2009. <http://www.has-sante.fr>

Hassan B, van der Stelt P, Sanderink G. Accuracy of three-dimensional measurements obtained from cone beam computed tomography surface-rendered images for cephalometric analysis: influence of patient scanning position. *Eur J Orthod.* 2009 Apr;31(2):129-34.

Hilgers ML, Scarfe WC, Scheetz JP, Farman AG. Accuracy of linear temporomandibular joint measurements with cone beam computed tomography and digital cephalometric radiography. *Am J Orthod Dentofacial Orthop* 2005; 128: 803-811.

Kamburoğlu K, Kolsuz E, Kurt H, Kılıç C, Ozen T, Semra Paksoy C. Accuracy of CBCT Measurements of a Human Skull. *J Digit Imaging.* 2010 Sep 21. [Epub ahead of print]

Kobayashi K, Shimoda S, Nakagawa Y, Yamamoto A. Accuracy in measurement of distance using limited cone-beam computerized tomography. *Int J Oral Maxillofac Implants* 2004; 19: 228-231.

Kumar V, Ludlow J, Soares Cevidanes LH, Mol A. In vivo comparison of conventional and cone beam CT synthesized cephalograms. *Angle Orthod* 2008; 78: 873-879.

Kumar V, Ludlow JB, Mol A, Cevidanes L. Comparison of conventional and cone beam CT synthesized cephalograms. *Dentomaxillofac Radiol* 2007; 36: 263-269.

Lagravère MO, Carey J, Toogood RW, Major PW. Three-dimensional accuracy of measurements made with software on cone-beam computed tomography images. *Am J Orthod Dentofacial Orthop.* 2008; 134: 112-116.

Lamichane M, Anderson NK, Rigali PH, Seldin EB, Will LA. Accuracy of reconstructed images from cone-beam computed tomography scans. *Am J Orthod Dentofacial Orthop.* 2009; 136: 156.e1-6; discussion 156-7.

Lascalea CA, Panella J, Marques MM. Analysis of the accuracy of linear measurements obtained by cone beam computed tomography (CBCT-NewTom). *Dentomaxillofac Radiol* 2004; 33: 291-294.

Leitlinie der DGZMK. Dentale Volumentomographie (DVT) - S1 Empfehlung. *Deutsche Zahnärztliche Zeitschrift* 64, 2009: 490 - 496.

Liu Y, Olszewski R, Alexandroni ES, Enciso R, Xu T, Mah JK. The validity of in vivo tooth volume determinations from cone-beam computed tomography. *Angle Orthod.* 2010; 80:160-166.

Loubele M, Van Assche N, Carpentier K, Maes F, Jacobs R, van Steenberghe D, Suetens P. Comparative localized linear accuracy of small-field cone-beam CT and multislice CT for alveolar bone measurements. *Oral Surg Oral Med Oral Pathol Oral Radiol Endod* 2008; 105: 512-518.

Ludlow JB, Laster WS, See M, Bailey LTJ, Hershey HG. Accuracy of measurements of mandibular anatomy in cone beam computed tomography images. *Oral Surg Oral Med Oral Pathol Oral Radiol Endod* 2007; 103: 534-542.

Luk LC, Pow EH, Li TK, Chow TW. Comparison of ridge mapping and cone beam computed tomography for planning dental implant therapy. *Int J Oral Maxillofac Implants* 2011; 26: 70-74.

Lund H, Grondahl K, Grondahl HG. Accuracy and precision of linear measurements in cone beam computed tomography Accuitomo tomograms obtained with different reconstruction techniques. *Dentomaxillofac Radiol* 2009; 38: 379-386.

Marmulla R, Wortche R, Muhling J, Hassfeld S. Geometric accuracy of the NewTom 9000 Cone Beam CT. *Dentomaxillofac Radiol* 2005; 34: 28-31.

- Mischkowski RA, Pulsfort R, Ritter L, Neugebauer J, Brochhagen HG, Keeve E, Zoller J E. Geometric accuracy of a newly developed cone-beam device for maxillofacial imaging. *Oral Surg Oral Med Oral Pathol Oral Radiol Endod* 2007; 104: 551-559.
- Moerenhout BA, Gelaude F, Swennen GR, Casselman JW, Van Der Sloten J, Mommaerts MY. Accuracy and repeatability of cone-beam computed tomography (CBCT) measurements used in the determination of facial indices in the laboratory setup. *J Craniomaxillofac Surg.* 2009; 37: 18-23.
- Moreira CR, Sales MA, Lopes PM, Cavalcanti MG. Assessment of linear and angular measurements on three-dimensional cone-beam computed tomographic images. *Oral Surg Oral Med Oral Pathol Oral Radiol Endod.* 2009; 108: 430-436.
- Moshiri M, Scarfe WC, Hilgers ML, Scheetz JP, Silveira AM, Farman AG. Accuracy of linear measurements from imaging plate and lateral cephalometric images derived from cone-beam computed tomography. *Am J Orthod Dentofacial Orthop* 2007; 132: 550-560.
- Naitoh M, Hirukawa A, Katsumata A, Ariji E. Evaluation of voxel values in mandibular cancellous bone: relationship between cone-beam computed tomography and multislice helical computed tomography. *Clin Oral Implants Res* 2009; 20: 503-506.
- Peck JN, Conte GJ. Radiologic techniques using CBCT and 3-D treatment planning for implant placement. *J Calif Dent Assoc* 2006; 36: 287-290.
- Periago DR, Scarfe WC, Moshiri M, Scheetz JP, Silveira AM, Farman AG. Kinematic accuracy and reliability of cone beam CT derived 3-dimensional images constructed using an orthodontic volumetric rendering program. *Angle Orthod* 2008; 78: 387-395.
- Pinsky HM, Dyda S, Pinsky RW, Misch KA, Sarment DP. Accuracy of three-dimensional measurements using cone-beam CT. *Dentomaxillofac Radiol* 2006; 35: 410-416.
- Razavi T, Palmer RM, Davies J, Wilson R, Palmer PJ. Accuracy of measuring the cortical bone thickness adjacent to dental implants using cone beam computed tomography. *Clin Oral Implants Res.* 2010; 21: 718-725.
- Sakabe J, Kuroki Y, Fujimaki S, Nakajima I, Honda K. Reproducibility and accuracy of measuring unerupted teeth using limited cone beam X-ray CT. *Dentomaxillofac Radiol* 2007; 36: 2-6.
- SEDENTEXCT Guideline Development Panel. Radiation Protection: Cone Beam CT for Dental and Maxillofacial Radiology Provisional Guidelines 2009 (v 1.1 May 2009). www.sedentext.eu
- Sherrard JF, Rossouw PE, Benson BW, Carrillo R, Buschang PH. Accuracy and reliability of tooth and root lengths measured on cone-beam computed tomographs. *Am J Orthod Dentofacial Orthop* 2010; 137(4 Suppl): S100-8.
- Stratemann SA, Huang JC, Maki K, Miller AJ, Hatcher DC. Comparison of cone beam computed tomography imaging with physical measures. *Dentomaxillofac Radiol* 2008; 37: 80-93.
- Suomalainen A, Vehmas T, Kortensniemi M, Robinson S, Peltola J. Accuracy of linear measurements using dental cone beam and conventional multislice computed tomography. *Dentomaxillofac Radiol* 2008; 37: 10-17.
- Tsutsumi K, Chikui T, Okamura K, Yoshiura K. Accuracy of linear measurement and the measurement limits of thin objects with cone beam computed tomography: effects of measurement directions and of phantom locations in the fields of view. *Int J Oral Maxillofac Implants.* 2011; 26: 91-100.
- Van Assche N, van Steenberghe D, Guerrero ME, Hirsch E, Schutyser F, Quirynen M, Jacobs R. Accuracy of implant placement based on pre-surgical planning of three-dimensional cone-beam images: a pilot study. *J Clin Periodontol* 2007; 34: 816-821.

Van Elslande D, Heo G, Flores-Mir C, Carey J, Major PW. Accuracy of mesiodistal root angulation projected by cone-beam computed tomographic panoramic-like images. *Am J Orthod Dentofacial Orthop*. 2010; 137 (4 Suppl):S94-9.

van Vlijmen OJC, Berge SJ, Swennen GRJ, Bronkhorst EM, Katsaros C, Kuijpers-Jagtman AM (2009). Comparison of cephalometric radiographs obtained from cone-beam computed tomography scans and conventional radiographs. *J Oral Maxillofac Surg* 2009; 67: 92-97.

Veyre-Goulet S, Fortin T, Thierry A. Accuracy of linear measurement provided by cone beam computed tomography to assess bone quantity in the posterior maxilla: a human cadaver study. *Clin Implant Dent Relat Res* 2008; 10: 226-230.

4.2: The developing dentition

Many children seek orthodontic treatment. For children in the mixed dentition stage, where there are abnormalities in eruption pattern, tooth position or signs of crowding, radiographs may be required to determine the presence, absence, position and condition of teeth. Most orthodontic appliance treatment takes place at around 12-13 years of age, at which stage radiographs may be necessary to confirm the presence, absence, position and condition of teeth as an aid to treatment planning.

Justification of X-ray examinations in children is especially important because of the higher risks associated with exposure in children (see section 2.4). Traditional radiological examination of children undergoing orthodontic assessment relies on a panoramic radiograph, supplemented by a lateral cephalometric radiograph in specific circumstances. Intraoral radiographs are also used according to patient-specific needs. In recent years, however, the availability of CBCT has led to this technique being used by some clinicians as a means of radiological examination. The recent review of Kapila et al (2011) provides a useful summary of the current status of CBCT in orthodontics.

For assessment of facial bone shape, position and inter-relationships, there must be a high accuracy of measurements made with CBCT. Since the previous review, a large number of studies have been published on dimensional accuracy (see Section 4.1.1), many using direct measurement of skeletal material as a reference standard. Broadly speaking, these can be summarised as demonstrating that dental CBCT has a high accuracy for measurements, with any differences between image-derived measurements and the reference standard being so small as to be clinically irrelevant.

The applications of dental CBCT in assessment of the developing dentition for orthodontics will be considered under two broad headings: localised applications to answer a specific question and generalised application for examination of the entire dento-facial region.

4.2.1 Localised applications of CBCT for the developing dentition

Unerupted tooth localisation

A frequent application of CBCT is for assessment of the position of an unerupted tooth, particularly where the tooth is impacted. In these cases, an integral aspect of the assessment is often the accurate identification of any resorption of adjacent teeth. Such a situation is most often seen where maxillary canines are ectopic and incisor roots are suspected of having undergone resorption (Walker et al 2005). Traditional radiological assessment relies upon the use of parallax movement between images taken with different perspectives. In some specialised centres, MSCT has been used for this purpose, so some studies have concentrated on this comparison of performance.

Teeth are relatively large objects, having good contrast with the surrounding bone. It is obvious that a three-dimensional imaging technique with acceptable measurement accuracy and little distortion will identify position of teeth with high diagnostic accuracy. A recent systematic review (Guerrero et al, 2011) identified only four studies in which diagnostic accuracy had been determined for CBCT in relation to impacted teeth against a reference standard, all of which related to mandibular third molars (reviewed in Section 4.1.1). Our systematic review also did not identify any diagnostic accuracy studies for inclusion relevant to orthodontics.

In the previous SEDENTEXCT review in 2009, the literature on this use of CBCT was dominated by case reports and series (see Table 4.1) and those of Liu et al (2007, 2008) were highlighted in view of their scale. On this occasion, however, three studies (Haney et al 2010; Botticelli et al 2010; Katheria et al 2010) were identified by the Panel which measured aspects of “Diagnostic Thinking Efficacy” and “Therapeutic Efficacy” (Fryback & Thornbury 1991). Haney et al (2010) in a clinical study of impacted maxillary canine teeth, showed that there were differences in diagnosis of tooth position between those made using conventional radiography and those made using CBCT, although this was only in a minority of observations. There were larger differences in treatment plans when the two imaging methods were compared, while confidence in diagnosis and treatment plans was greater when CBCT was used. Botticelli et al (2010) showed that the understanding of canine position was different when CBCT was used compared with conventional imaging and that, in a minority of cases, treatment decisions were different. Similar findings for defining canine and supernumerary tooth position were reported by Katheria et al (2010), while observers in their study scored a significantly higher proportion of CBCT examinations as “very useful” in treatment planning than for conventional radiographic examinations. While there is a message here that the availability of CBCT changes diagnosis and treatment plans for a proportion of cases, it must be remembered that this may not be translated into better outcomes for patients.

Despite the expected advantage of CBCT in tooth localisation, it is important to consider the impact upon management of patients, the increased radiation dose and the likely higher cost of CBCT examinations. Conventional radiography has served dentists and specialist orthodontists well over many years, and the Panel concluded that there is a need for research demonstrating changed (and improved) outcomes for patients before widespread use of CBCT for this purpose could be considered. An exception to this would be where current practice is to use MSCT for localisation of

unerupted teeth (Alqerban et al, 2009a). In such cases, CBCT is likely to be preferred over MSCT if dose is lower. In any case, radiological examination of maxillary canines is not usually necessary before 10 years of age.

For the localised assessment of an impacted tooth (including consideration of resorption of an adjacent tooth) where the current imaging method of choice is MSCT, CBCT may be preferred because of reduced radiation dose

GP

External resorption in relation to unerupted teeth

Assessment of impacted tooth position also involves assessment of the presence or absence of resorption in adjacent teeth. This application of CBCT has been considered in several case series and non-systematic reviews (Table 4.1). The review of Alqerban et al (2009a) considered this aspect in detail for the maxillary canine.

The Panel identified one relevant study for formal appraisal in the systematic review of diagnostic accuracy (Alqerban et al 2009b) in which accuracy of diagnosis of simulated resorption cavities in a skull was measured for panoramic radiography and two CBCT systems. Their results showed that, overall, sensitivity and specificity of CBCT were higher. Unfortunately their study did not include intraoral radiography, which would normally be used in assessment of impacted canines in this situation. Nonetheless, the studies on detection of root resorption in an endodontic context, in which intraoral radiography was the comparator imaging method (see Section 4.3.4), probably have relevance here.

Three clinical studies have considered resorption in relation to impacted teeth from a “Diagnostic Thinking Efficacy” and “Therapeutic Efficacy” perspective. The study of Haney et al (2010) on impacted maxillary canines reported that there was agreement between conventional and CBCT imaging on diagnosis of root resorption in the majority of assessments, while intra-rater reliability was lower for CBCT based assessments. Katheria et al (2010) found a significantly greater proportion of cases were scored by observers as showing resorption, although there was no consideration of the possibility of false positive scores. Alqerban et al (2011) compared observers’ detection of root resorption in relation to impacted canine teeth in a clinical study with no reference standard. They reported a higher detection rate of “slight” resorption and a lower detection rate of “no resorption” using CBCT than when using panoramic radiographs, although they did not use intraoral radiographs for comparison.

The results of these studies should stimulate a note of caution. While it seems likely that the three-dimensional information of CBCT will identify resorption of roots more effectively than conventional intraoral radiographs, particularly on the facial and palatal surfaces, there is no research evidence to suggest that this information, or any

Table 4.1: Orthodontic applications of CBCT identified and reviewed

Application of CBCT for orthodontics	Reference
Cleft palate assessment	Hamada et al 2005 Mussig et al 2005 Oberoi et al 2009 Oka et al 2006 Schneiderman et al 2009 Wortche et al 2006
Tooth position and localisation	Bedoya and Park 2009 Chaushu et al 2004 Gracco et al 2009 Kau et al 2005 Kau et al 2009 Nakajima et al 2005 Walker et al 2005 Liu et al 2007 Liu et al 2008 Mussig et al 2005 Swart et al 2008
Resorption related to impacted teeth	Kau et al 2005 Liu et al 2008
Measuring bone dimensions for mini-implant placement	Baumgaertel, 2009 Baumgaertel & Hans 2009a Baumgaertel et al 2009b Gracco et al 2006 Gracco et al 2007 Gracco et al 2008 Kim et al 2007 Park & Cho, 2009
For rapid maxillary expansion	Christie et al 2010 Garrett et al 2008 King et al 2007
3-dimensional cephalometry	Baumrind et al 2003
Surface imaging integration	Swennen & Scutyser 2006
Airway assessment	Maal et al 2008 Aboudara et al 2003 Kau et al 2005
Age assessment	Shi et al 2007 Yang et al 2006
Investigation of orthodontic-associated paraesthesia	Erickson et al 2003

changes in treatment, would alter the eventual outcomes. The Panel concluded that there was no strong evidence to support using CBCT as a “first line” imaging method for assessment of impacted maxillary canine or supernumerary teeth in the context of root resorption diagnosis, but that it may be indicated when conventional intraoral radiography did not supply adequate information.

CBCT may be indicated for the localised assessment of an impacted tooth (including consideration of resorption of an adjacent tooth) where the current imaging method of choice is conventional dental radiography and when the information cannot be obtained adequately by lower dose conventional (traditional) radiography

C

For the localised assessment of an impacted tooth (including consideration of resorption of an adjacent tooth), the smallest volume size compatible with the situation should be selected because of reduced radiation dose. The use of CBCT units offering only large volumes (craniofacial CBCT) requires very careful justification and is generally discouraged

GP BP

Cleft palate

MSCT is a widely accepted method of assessing clefts, despite the significant radiation dose. The use of CBCT in this application has been the subject of several non-systematic reviews and descriptive studies (Müssig et al 2005; Hamada et al 2005; Wörtche et al 2006; Korbmacher et al 2007). Three-dimensional information can be used to determine the volume of bone needed for grafting and the adequacy of bone fill after surgery (Oberoi et al 2009; Shirota et al 2010). The Panel found this application of CBCT to be the simplest to support, in view of the established use of three-dimensional images and the potentially lower dose of CBCT.

Where the current imaging method of choice for the assessment of cleft palate is MSCT, CBCT may be preferred if radiation dose is lower. The smallest volume size compatible with the situation should be selected because of reduced radiation dose

GP

Temporary orthodontic anchorage using “mini-implants”

Several studies have used CBCT to measure the available bone thickness for placing temporary anchorage devices (TADs), also known as mini-implants (Gracco et al 2006; King et al 2006; Gracco et al 2007; Gracco et al 2008; Kim et al 2007; King et al 2007; Baumgaertel 2009; Fayed et al 2010). In our previous review it was noted that at the time *“it was not clear when reviewing these studies whether the aim was to measure bone thickness (using CBCT as a convenient method of assessment) or whether CBCT was being proposed as a routine diagnostic tool”*. Subsequently, it now appears that CBCT is being used by some as a clinical tool prior to placing TADs to identify optimal position and to avoid damage to roots (Lai et al 2010; Kapila et al 2011). The use of surgical guides based on CBCT data has also been suggested (Miyazawa et al 2010). Jung et al (2010) evaluated whether CT or CBCT was needed preoperatively for placement of TADs; they found that three dimensional imaging was only needed in rare cases of borderline dimensions.

CBCT is not normally indicated for planning the placement of temporary anchorage devices in orthodontics

GP

4.2.2 Generalized application of CBCT for the developing dentition

Large volume (craniofacial) CBCT, imaging at least the entire facial skeleton, is currently being used as a routine tool for orthodontic-related radiological assessment by some clinicians (Kapila et al 2011; Smith et al 2011), particularly outside Europe. In view of the radiation doses involved and the (largely) paediatric age group of patients, this practice has become controversial and requires very critical consideration.

The European Guidelines on Radiation Protection in Dental Radiology (European Commission, 2004) highlighted the research performed, prior to the introduction of CBCT, which shows that clinical indicators and algorithms can reduce the numbers of radiographs without compromising patient treatment. Various studies have shown that radiographic information changes diagnosis and treatment plans in a minority of patients and there is specific evidence that cephalometric radiography is not always contributory to treatment planning (Han et al 1991; Bruks et al 1999; Nijkamp et al 2008; Devereux et al 2011). A flow-chart to support clinical decision making on the need for lateral cephalograms was included in the British Orthodontic Society Guidelines of 2002 and in a recent new edition (Isaacson et al 2008). Similar algorithms for selecting radiographs for orthodontic patients have been presented in European Guidelines (European Commission, 2004).

In our current review, no studies were identified relevant to “Diagnostic Accuracy”. This was not surprising, bearing in mind that orthodontic diagnosis does not normally

involve detection of pathosis in the usual sense. Studies of measurement accuracy (see Section 4.1.1) are highly relevant to the tasks involved in orthodontic diagnosis and treatment planning and suggest that CBCT can produce accurate depictions of tooth size, tooth inter-relationships and related bony anatomy. There is evidence that cephalograms synthesised from CBCT volume datasets are accurate (Cattaneo et al 2008; Kumar et al 2007; Kumar et al 2008), although existing guidelines state that it is inappropriate to perform CBCT solely for the purposes of reconstructing two-dimensional panoramic and cephalometric images (Health Protection Agency, 2009), a view fully supported by the SEDENTEXCT Panel.

As in our previous review, the Panel felt that much of the literature on using large volume CBCT for routine orthodontic diagnosis and treatment was anecdotal, case report- and opinion-based, with a lack of evidence of significant clinical impact. While localised uses of CBCT (Section 4.2.1) have supporting research evidence, no scientifically valid evidence was identified to support the use of large volume CBCT at any stage of orthodontic treatment. Amongst the justifications of using CBCT instead of conventional radiography are that it allows accurate establishment of “boundary conditions” (Kapila et al 2011) in patients with bucco-lingually narrow alveolar bone, compromised periodontal or gingival anatomy and where movement of a tooth may involve translocation past another tooth or obstruction. The Panel recognised that there may be instances where three-dimensional information could assist in patient management, but could not find evidence to define these situations. The use of three-dimensional cephalometry has been presented by some authors as a means of improved diagnosis and management, but the evidence for this opinion is absent and there is no universally accepted method of three-dimensional cephalometric landmark analysis.

As such, the Panel could not recommend CBCT as a standard method of diagnosis and treatment planning in orthodontic practice. This is in accord with national guidelines within Europe (Isaacson et al, 2008; Haute Autorité de Santé 2009; Leitlinie der DGZMK, 2009) and the recommendation of the American Association of Orthodontists (American Association of Orthodontists, 2010). The Panel could, however, see the potential value of large volume CBCT for assessment of patients with complex craniofacial deformity requiring surgical or combined surgical/orthodontic intervention at 16 years or over as part of planning for the definitive procedure. Serial “monitoring” of skeletal growth should be discouraged.

*Large volume CBCT should not be used routinely
for orthodontic diagnosis*

D

For complex cases of skeletal abnormality, particularly those requiring combined orthodontic/surgical management, large volume CBCT may be justified in planning the definitive procedure, particularly where MSCT is the current imaging method of choice

GP

When health professionals change their practice to adopt a more expensive diagnostic technique, particularly where there are radiation-related risks in a predominantly young patient age group, the onus is upon them to demonstrate significant improvement in patient outcomes.

Research is needed to define robust guidance on clinical selection for large volume CBCT in orthodontics, based upon quantification of benefit to patient outcome

GP

4.2.3 References

Aboudara CA, Hatcher D, Nielsen IL, Miller A. A three-dimensional evaluation of the upper airway in adolescents. *Orthodontics & Craniofacial Research* 2003; 6 Suppl 1: 173-175.

Alqerban A, Jacobs R, Lambrechts P, Loozen G. Root resorption of the maxillary lateral incisor caused by impacted canine: a literature review. *Clin Oral Investigation* 2009a; 13: 247-255.

Alqerban A, Jacobs R, Souza PC, Willems G. In-vitro comparison of 2 cone-beam computed tomography systems and panoramic imaging for detecting simulated canine impaction-induced external root resorption in maxillary lateral incisors. *Am J Orthod Dentofacial Orthop.* 2009b; 136: 764.e1-11; discussion 764-5.

Alqerban A, Jacobs R, Fieuws S, Willems G. Comparison of two cone beam computed tomographic systems versus panoramic imaging for localization of impacted maxillary canines and detection of root resorption. *Eur J Orthod.* 2011; 33: 93-102.

American Association of Orthodontists. *Statement on the role of CBCT in orthodontics (26-10 H)*. eBulletin May 7 2010. www.aaomembers.org/Resources/Publications/ebulletin-05-06-10.cfm. [Accessed 18 March 2011].

Ballrick JW, Palomo JM, Ruch E, Amberman BD, Hans MG. Image distortion and spatial resolution of a commercially available cone-beam computed tomography machine. *Am J Orthod Dentofacial Orthop* 2008; 134: 573-582.

Baumgaertel S. Quantitative investigation of palatal bone depth and cortical bone thickness for mini-implant placement in adults. *Am J Orthod Dentofacial Orthop.* 2009 Jul;136(1):104-8.

Baumrind S, Carlson S, Beers A, Curry S, Norris K, Boyd RI. Using three-dimensional imaging to assess treatment outcomes in orthodontics: a progress report from the University of the Pacific. *Orthod Craniofac Res* 2003; 6 Suppl 1: 132-142.

Bedoya MM, Park JH. A review of the diagnosis and management of impacted maxillary canines. *J Am Dent Assoc* 2009; 140(12): 1485-93

Botticelli S, Verna C, Cattaneo PM, Heidmann J, Melsen B. Two- versus three-dimensional imaging in subjects with unerupted maxillary canines. *Eur J Orthod*. 2010 Dec 3. [Epub ahead of print]

Bruks A, Enberg K, Nordqvist I, Hansson A, Jansson L, Svenson B. Radiographic examinations as an aid to orthodontic diagnosis and treatment planning. *Swed Dent J* 1999; 23: 77-85.

Baumgaertel, S. Quantitative investigation of palatal bone depth and cortical bone thickness for mini-implant placement in adults. *Am J Orthod Dentofacial Orthop* 2009; 136(1): 104-8 .

Baumgaertel, S, Hans, MG. Assessment of infrazygomatic bone depth for mini-screw insertion. *Clin Oral Implants Res* 2009; 20(6): 638-42.

Baumgaertel, S, Hans, MG. Buccal cortical bone thickness for mini-implant placement. *Am J Orthod Dentofacial Orthop* 2009; 136(2): 230-5.

Cattaneo PM, Bloch CB, Calmar D, Hjortshøj M, Melsen B. Comparison between conventional and cone-beam computed tomography-generated cephalograms. *Am J Orthod Dentofacial Orthop* 2008; 134: 798-802.

Chaushu S, Chaushu G, Becker A. The role of digital volume tomography in the imaging of impacted teeth. *World J Orthod* 2004; 5: 120-132.

Christie KF, Boucher N, Chung C-H. Effects of bonded rapid palatal expansion on the transverse dimensions of the maxilla: a cone-beam computed tomography study. *Am J Orthod Dentofacial Orthop* 2010; 137(4 Suppl): S79-85

Devereux L, Moles D, Cunningham SJ, McKnight M. How important are lateral cephalometric radiographs in orthodontic treatment planning? *Am J Orthod Dentofacial Orthop*. 2011;139: e175-81.

Erickson M, Caruso JM, Leggit L. Newtom QR-DVT 9000 imaging used to confirm a clinical diagnosis of iatrogenic mandibular nerve paresthesia. *J Calif Dent Assoc* 2003; 31: 843-845.

Fayed MM, Pazera P, Katsaros C. Optimal sites for orthodontic mini-implant placement assessed by cone beam computed tomography. *Angle Orthod* 2010; 80: 939-951.

Garrett BJ, Caruso JM, Rungcharassaeng K, Farrage JR, Kim JS, Taylor GD. Skeletal effects to the maxilla after rapid maxillary expansion assessed with cone-beam computed tomography. *Am J Orthod Dentofacial Orthop* 2008; 134: 8-9.

Gracco A, Lombardo L, Cozzani M, Siciliani G. Quantitative evaluation with CBCT of palatal bone thickness in growing patients. *Prog Orthod* 2006; 7: 164-174.

Gracco A, Luca L, Cozzani M, Siciliani G. Assessment of palatal bone thickness in adults with cone beam computerised tomography. *Aust Orthod J* 2007; 23: 109-113.

Gracco A, Lombardo L, Cozzani M, Siciliani G. Quantitative cone-beam computed tomography evaluation of palatal bone thickness for orthodontic miniscrew placement (2008) *Am J Orthod Dentofacial Orthop* 2008; 134: 361-369.

Gracco A, Lombardo L, Mancuso G, Gravina V, Siciliani, G. Upper incisor position and bony support in untreated patients as seen on CBCT. *Angle Orthodontist* 2009; 79(4): 692-702

Guerrero ME, Shahbazian M, Elsiens Bekkering G, Nackaerts O, Jacobs R, Horner K. The diagnostic efficacy of cone beam CT for impacted teeth and associated features: a systematic review. *J Oral Rehabil* 2011; 38: 208-216.

Hahn W, Fricke-Zech S, Fricke J, Gruber RM, Dullin C, Zapf A, Hannig C, Kubein-Meesenburg D, Sadat-Khonsari R. Detection and size differentiation of simulated tooth root defects using flat-panel volume computerized tomography (fpVCT). *Oral Surg Oral Med Oral Pathol Oral Radiol Endod* 2009; 107:272-278.

Han UK, Vig. KW, Weintraub JA, Vig PS, Kowalski CJ. Consistency of orthodontic treatment decisions relative to diagnostic records, *Am J Orthod Dentofacial Orthop* 1991; 100: 212–219.

Haney E, Gansky SA, Lee JS, Johnson E, Maki K, Miller AJ. Comparative analysis of traditional radiographs and cone-beam computed tomography volumetric images in the diagnosis and treatment planning of maxillary impacted canines. *Am J Orthod Dentofacial Orthop* 2010; 137: 590-597.

Hamada Y, Kondoh T, Noguchi K, Iino M, Ishii H, Mishima A, Kobayashi K, Seto K. Application of limited cone beam computed tomography to clinical assessment of alveolar bone grafting: a preliminary report. *Cleft palate Craniofac J* 2005; 42: 128-137.

Haute Autorité de Santé. Tomographie Volumique a Faisceau Conique de la Face (Cone Beam Computerized Tomography). Rapport d'évaluation Technologique. Service évaluation des actes professionnels. Saint-Denis La Plaine: Haute Autorité de Santé, 2009. <http://www.has-sante.fr>

Health Protection Agency. The Radiation Protection Implications of the Use of Cone Beam Computed Tomography (CBCT) in dentistry – What You Need To Know. Chilton: Health Protection Agency, 2009.

Isaacson KG, Thom AR, Horner K, Whaites E. Orthodontic Radiographs. Guidelines for the use of radiographs in orthodontics. British Orthodontic Society: London, 2008.

Jung BA, Wehrbein H, Wagner W, Kunkel M. Preoperative Diagnostic for Palatal Implants: Is CT or CBCT Necessary? *Clin Implant Dent Relat Res*. 2010; Feb 3. [Epub ahead of print]

Kapila S, Conley RS, Harrell Jr WE. The current status of cone beam computed tomography imaging in orthodontics. *Dentomaxillofac Radiol* 2011; 40: 24-34.

Katheria BC, Kau CH, Tate R, Chen JW, English J, Bouquot J. Effectiveness of impacted and supernumerary tooth diagnosis from traditional radiography versus cone beam computed tomography. *Pediatr Dent*. 2010; 32: 304-309.

Kau CH, Richmond S, Palomo JM, Hans MG. Three-dimensional cone beam computerized tomography in orthodontics. *J Orthod* 2005; 32: 282-293.

Kau CH, Pan P, Gallerano RL, English JD. A novel 3D classification system for canine impactions--the KPG index. *The International Journal of Medical Robotics and Computer Assisted Surgery: MRCAS* 2009; 5(3): 291-6

Kim S, Choi Y, Hwang E, Chung K, Kook Y, Nelson G. Surgical positioning of orthodontic mini-implants with guides fabricated on models replicated with cone-beam computed tomography. *Am J Orthod Dentofacial Orthop* 2007; 131: S82-S89.

King KS, Lam EW, Faulkner MG, Heo G, Major PW. Predictive factors of vertical bone depth in the paramedian palate of adolescents." *Angle Orthod* 2006; 76: 745-751.

King KS, Lam EW, Faulkner MG, Heo G, Major PW. Vertical bone volume in the paramedian palate of adolescents: a computed tomography study. *Am J Orthod Dentofacial Orthop* 2007; 132: 783-788.

Korbmacher H, Kahl-Nieke B, Schollchen M, Heiland M. Value of two cone-beam computed tomography systems from an orthodontic point of view. *J Orofac Orthop* 2007; 68: 278-289.

- Kumar V. In Vivo Comparison of Conventional and Cone Beam CT Synthesized Cephalograms. *Angle Orthodont* 2008; 78: 873-879.
- Kumar V, Ludlow JB, Mol A, Cevidane L. Comparison of conventional and cone beam CT synthesized cephalograms. *Dentomaxillofac Radiol* 2007; 36: 263-269.
- Lai RF, Zou H, Kong WD, Lin W. Applied anatomic site study of palatal anchorage implants using cone beam computed tomography. *Int J Oral Sci* 2010; 2: 98-104.
- Lane C, Harrell W. Completing the 3-dimensional picture. *Am J Orthod Dentofacial Orthop* 2008; 133: 612-620.
- Lascalea CA, Panella J, Marques MM. Analysis of the accuracy of linear measurements obtained by cone beam computed tomography (CBCT-NewTom). *Dentomaxillofac Radiol* 2004; 33: 291-294.
- Leitlinie der DGZMK. Dentale Volumentomographie (DVT) - S1 Empfehlung. *Deutsche Zahnärztliche Zeitschrift* 64, 2009: 490 - 496.
- Liedke GS, Dias de Silveira HE, Dias de Silveira HL, Dutra V, Poli de Figueiredo JA. Influence of Voxel Size in the Diagnostic Ability of Cone Beam Tomography to Evaluate Simulated External Root Resorption. *J Endod* 2009; 35: 233-235.
- Liu D, Zhang W, Zhang z, Wu Y, Ma X. Three-dimensional evaluations of supernumerary teeth using cone-beam computed tomography for 487 cases. *Oral Surg Oral Med Oral Pathol Oral Radiol Endod* 2007; 103: 403-411.
- Liu D, Zhang W, Zhang z, Wu Y, Ma X. Localization of impacted maxillary canines and observation of adjacent incisor resorption with cone-beam computed tomography. *Oral Surg Oral Med Oral Pathol Oral Radiol Endod* 2008; 105: 91-98.
- Loubele M, Van Assche N, Carpentier K, Maes F, Jacobs R, Van Steenberghe D, Suetens P. Comparative localized linear accuracy of small-field cone-beam CT and multislice CT for alveolar bone measurements. *Oral Surg Oral Med Oral Pathol Oral Radiol Endod* 2008; 105: 512-518.
- Ludlow JB, Laster WS, See M, Bailey LTJ, Hershey HG. Accuracy of measurements of mandibular anatomy in cone beam computed tomography images. *Oral Surg Oral Med Oral Pathol Oral Radiol Endod* 2007; 103: 534-542.
- Maal TJJ, Plooi J, Rangel FA, Mollemans W, Schutyser AC, Bergé SJ. The accuracy of matching three-dimensional photographs with skin surfaces derived from cone-beam computed tomography. *Int J Oral Maxillofac Surg* 2008; 37: 641-646.
- Marmulla R, Wörtche R, Muhling J, Hassfeld S. Geometric accuracy of the NewTom 9000 Cone Beam CT. *Dentomaxillofac Radiol* 2005; 34: 28-31.
- Mischkowski RA, Pulsfort R, Ritter L, Neugebauer J, Brochhagen HG, Keeve E, Zoller J E. Geometric accuracy of a newly developed cone-beam device for maxillofacial imaging. *Oral Surg Oral Med Oral Pathol Oral Radiol Endod* 2007; 104: 551-559.
- Miyazawa K, Kawaguchi M, Tabuchi M, Goto S. Accurate pre-surgical determination for self-drilling miniscrew implant placement using surgical guides and cone-beam computed tomography. *Eur J Orthod* 2010; 32: 735-740.
- Moshiri M, Scarfe WC, Hilgers ML, Scheetz JP, Silveira AM, Farman AG. Accuracy of linear measurements from imaging plate and lateral cephalometric images derived from cone-beam computed tomography. *Am J Orthod Dentofacial Orthop* 2007; 132: 550-560.
- Müssig E, Wörtche R, Lux CJ. Indications for digital volume tomography in orthodontics. *J Orofac Orthop* 2005; 66: 241-249.

Nakajima A, Sameshima GT, Arai Y, Homme Y, Shimizu N, Dougherty H. Two- and three-dimensional orthodontic imaging using limited cone beam-computed tomography. *Angle Orthod* 2005; 75: 895-903.

Nijkamp P, Habets L, Aartman I, Zentner A. The influence of cephalometrics on orthodontic treatment planning. *Eur J Orthod* 2008; 30: 630-635.

Oberoi S, Chigurupati R, Gill P, Hoffman WY, Vargervik K. Volumetric assessment of secondary alveolar bone grafting using cone beam computed tomography. *Cleft Palate Craniofac J*. 2009 Sep;46(5):503-11.

Ogawa T, Enciso R, Shintaku WH, Clark GT. Evaluation of cross-section airway configuration of obstructive sleep apnea. *Oral Surg Oral Med Oral Pathol Oral Radiol Endod* 2007; 103: 102-108.

Oka, H, Moriguchi, T, Sato, Y. Postoperative assessment of secondary bone grafting to the alveolar cleft using three-dimensional cone beam computed tomography. *Japanese Journal of Plastic and Reconstructive Surgery* 2006; 49(1): 49-57.

Park J, Cho HJ. Three-dimensional evaluation of interradicular spaces and cortical bone thickness for the placement and initial stability of microimplants in adults. *Am J Orthod Dentofacial Orthop* 2009; 136(3): 314.e1-12; discussion 314-5

Peck JN, Conte GJ. Radiologic techniques using CBCT and 3-D treatment planning for implant placement. *J Calif Dent Assoc* 2006; 36: 287-290.

Periago DR, Scarfe WC, Moshiri M, Scheetz JP, Silveira AM, Farman AG. Kinematic accuracy and reliability of cone beam CT derived 3-dimensional images constructed using an orthodontic volumetric rendering program. *Angle Orthod* 2008; 78: 387-395.

Rungcharassaeng K, Caruso JM, Kan JY, Kim J, Taylor G. Factors affecting buccal bone changes of maxillary posterior teeth after rapid maxillary expansion. *Am J Orthod Dentofacial Orthop* 2007; 132: 428.e1-8.

Schneiderman ED, Xu H, Salyer, KE. Characterization of the maxillary complex in unilateral cleft lip and palate using cone-beam computed tomography: a preliminary study. *J Craniofac Surg* 2009; 20 Suppl 2: 1699-710

Shi H, Scarfe WC, Farman AG. (2007). Three-dimensional reconstruction of individual cervical vertebrae from cone-beam computed-tomography images. *Am J Orthod Dentofacial Orthop* 2007; 131: 426-432.

Shirota T, Kurabayashi H, Ogura H, Seki K, Maki K, Shintani S. Analysis of bone volume using computer simulation system for secondary bone graft in alveolar cleft. *Int J Oral Maxillofac Surg* 2010; 39: 904-908.

Smith BR, Park JH, Cederberg RA. An evaluation of cone-beam computed tomography use in postgraduate orthodontic programs in the United States and Canada. *J Dent Educ*. 2011; 75: 98-106.

Stratemann SA, Hunag JC, Maki K, Miller AJ, Hatcher DC. Comparison of cone beam computed tomography imaging with physical measures. *Dentomaxillofac Radiol* 2008; 37: 80-93.

Suomalainen A, Vehmas T, Kortensniemi M, Robinson S, Peltola J. Accuracy of linear measurements using dental cone beam and conventional multislice computed tomography. *Dentomaxillofac Radiol* 2008; 37: 10-17.

Swart RJ, Kiekens RMA, Borstlap WA, Kuijpers-Jagtman AM. Orthodontics in general practice 4. Impaction of maxillary front teeth. *Nederlands Tijdschrift voor Tandheelkunde* 2008; 115(5): 252-8

Swennen GRJ, Schutyser F. Three-dimensional cephalometry: spiral multi-slice vs cone-beam computed tomography." *Am J Orthod Dentofacial Orthop* 2006; 130: 410-416.

Wörtche R, Hassfeld S, Lux CJ, Müssig E, Hensley FW, Krempien R, Hofele C. Clinical application of cone beam digital volume tomography in children with cleft lip and palate. *Dentomaxillofac Radiol* 2006; 35: 88-94.

Walker L, Enciso R, Mah J. Three-dimensional localization of maxillary canines with cone-beam computed tomography. *Am J Orthod Dentofacial Orthop* 2005; 128: 418-423.

Yang F, Jacobs R, Willems G. Dental age estimation through volume matching of teeth imaged by cone-beam CT. *Forensic Science International* 2006; 159 Suppl 1: S78-83

4.3: Restoring the dentition

4.3.1: Dental caries diagnosis

The use of CBCT as part of caries detection and diagnosis has been the subject of several laboratory research studies on extracted teeth. The relative ease of obtaining a valid reference standard means that the studies provide useful evidence of diagnostic value. In the previous review, we noted that much of the research had been performed using “limited” CBCT (small volumes with specific equipment) and that results are not transferable to all CBCT machines, as pointed out by Haiter-Neto et al (2008). Since then, several studies have been performed with alternative CBCT systems. Also since our previous review, a few studies have been performed which study occlusal caries.

Seven studies of proximal caries detection were included in the systematic review (Tsuchida et al 2007; Haiter-Neto et al 2008; Young et al 2009; Qu et al 2010; Kayipmaz et al 2010; Senel et al 2010; Zhang et al 2011). In five of these, in which Receiver-Operating Characteristic Curve (ROC) analysis was used, there was no significant difference in diagnostic performance between the CBCT systems and intraoral radiography. The other two studies (Haiter-Neto et al 2008; Young et al 2009), in which sensitivity and specificity were presented rather than ROC values, found higher sensitivity for detection of proximal dentine caries with a small volume, high resolution CBCT system, although Haiter-Neto et al (2008) reported no difference in overall true scores between CBCT and conventional radiographic imaging.

Three studies of occlusal caries detection were included in the systematic review (Haiter-Neto et al 2008; Young et al 2009; Kayipmaz et al 2010). All of these present data indicating increased sensitivity for occlusal caries diagnosis compared with conventional radiography. Young et al (2009) found that this was accompanied by a loss of specificity, while Haiter-Neto et al (2008) found (as with proximal caries detection) no differences in overall true scores. Any deterioration in specificity observed with CBCT imaging may reflect artefactual radiolucencies beneath the cusp enamel, reported by Young et al (2009). The studies of Kamboroglu et al (2010a and 2010b) could not be included in the systematic review, as they did not present recognised data on diagnostic accuracy; their work, however, suggests that occlusal caries depth measurements from CBCT correlate with histopathology better than intraoral radiographic images.

The current evidence suggests that limited CBCT has a similar diagnostic accuracy to conventional radiography for the detection of proximal caries in posterior teeth *in vitro*. For occlusal caries detection, the reports of higher sensitivity with CBCT suggest that further research would be of value. The representation of caries depth may be superior (Akdeniz et al 2006; Haiter-Neto et al 2008; Tsuchida et al 2007; Kamboroglu et al 2010a). One practical challenge to using CBCT for caries detection in the clinical situation, not addressed in the laboratory studies, is that metallic restorations will produce artefacts that would reduce diagnostic accuracy.

The Panel concluded that the evidence did not support the clinical use of CBCT for caries detection and diagnosis. Nonetheless, CBCT examinations performed for other

purposes should be carefully examined for caries lesions shown fortuitously when performing a clinical evaluation (report).

CBCT is not indicated as a method of caries detection and diagnosis

B

4.3.2: Periodontal assessment

The diagnosis of periodontal diseases depends on a clinical examination. This may be supplemented by radiological examination if this is likely to provide additional information that could potentially change patient management or prognosis.

Radiographs do not have a role in diagnosis of periodontal disease, but are used as a means of demonstrating the hard tissue effects of periodontal disease, particularly the bony attachment loss. As pointed out in previous guidelines (European Commission, 2004), there is no clear evidence to support any robust recommendations on selection of radiological examinations. Those guidelines recommended that “existing radiographs, e.g. bitewing radiographs taken for caries diagnosis, should be used in the first instance”.

Conventional two-dimensional radiographs have significant limitations in demonstrating the periodontal attachment of teeth. Two-dimensional images do not show irregular bone defects or buccal/lingual attachments clearly. The attraction of a three-dimensional image is, therefore, considerable. The scientific literature on periodontal uses of CBCT is small and the Panel identified only two *in vitro* studies suitable for systematic review of diagnostic accuracy (Mol & Balasundaram 2008; Noujeim et al 2009). Using ROC analysis, Mol & Balasundaram (2008) demonstrated that one CBCT system was superior to conventional intraoral radiographs for diagnosis of the presence of periodontal bone loss in dried skeletal material. Noujeim et al (2009) created interradicular bone cavities in mandibles and found that a CBCT system was more accurate in detection of these than conventional radiography.

Several other studies were informally reviewed. Limited volume CBCT can provide accurate depiction of periodontal bone defects with good dimensional accuracy in laboratory studies (Mengel et al, 2005; Pinsky et al 2005; Mol & Balasundaram 2008), but with the latter study showing a less impressive performance for CBCT in the anterior regions. Interestingly, however, one study reported no significant differences in linear measurements between bone sounding, conventional radiography and CBCT (Misch et al 2006), although buccal/lingual measurements could not be made by radiography. This lack of statistically significant difference between conventional and CBCT images was also reported in another laboratory study (Vandenberghe et al 2007). In a large *ex vivo* study, however, CBCT measurement accuracy was significantly better than intraoral radiography when cross-sectional images were used, but not when a panoramic reconstruction was employed (Vandenberghe et al 2008). The same study showed that CBCT was superior to intraoral radiography for crater and furcation defect imaging, reflecting case reports and non-systematic review opinion (Ito et al 2001; Kasaj & Willershausen 2007; Naitoh, 2006).

In a small clinical study of patients selected for periodontal surgery for maxillary molar furcation lesions, Walter et al (2010) found that pre-surgical CBCT estimates of furcation involvement of these teeth had a high level of agreement with intra-surgical findings. Takane et al (2010) used CBCT to facilitate guided tissue regeneration by allowing the prefabrication of the regeneration membrane material, while Bhatavadekar & Paquette (2008) reported the potential role of CBCT in evaluating the response to surgery and regenerative treatment of intrabony defects.

Overall, the literature related to use of CBCT in periodontal imaging is small, mainly laboratory-based and involves a limited number of CBCT systems. In terms of detection of periodontal bone loss, laboratory studies do not permit a comparison of CBCT with the primary diagnostic method *i.e.* probing of pockets. Furthermore, the impact of three-dimensional images upon management decisions and treatment impact in clinical practice has not been considered. Nonetheless, the general direction of the case series in the literature suggests that CBCT may have a role to play in the management of complex periodontal defects for which surgery is the treatment option.

CBCT is not indicated as a routine method of imaging periodontal bone support

C

Limited volume, high resolution CBCT may be indicated in selected cases of infra-bony defects and furcation lesions, where clinical and conventional radiographic examinations do not provide the information needed for management

C

Where CBCT images include the teeth, care should be taken to check for periodontal bone levels when performing a clinical evaluation (report)

GP

4.3.3: Assessment of periapical disease

Diagnosis of periapical inflammatory pathosis is a common and important task for dentists. A number of case reports and non-systematic reviews have highlighted the value of CBCT for identification of periapical lesions in selected cases (Nakata et al 2006; Cotton et al, 2007; Patel et al, 2007). The research studies addressing this

aspect of use of CBCT are limited by the extreme, probably insurmountable, difficulty of obtaining a true reference standard in human clinical studies. Our previous SEDENTEXCT review concluded that there was some evidence that CBCT identifies more periapical lesions on posterior teeth than traditional radiography, but further research studies assessing diagnostic accuracy were required. A subsequent study showed that CBCT identified more, and larger, periapical bone defects following apicectomy than did conventional radiography (Christiansen et al 2009). Ózen et al (2009) found improved observer agreement values when artificial periapical lesions were assessed with CBCT compared with conventional imaging. In the current review, four studies were identified that were eligible for systematic review (Stavropoulos & Wenzel, 2007; de Paula-Silva et al 2009; Patel et al 2009a; Soğur et al 2009), all of which were laboratory studies. Research designs were varied, using human and animal teeth and artificially created periapical lesions, but included one study performed in dogs *in vivo* with histopathologically validated periapical inflammatory lesions (de Paula-Silva et al 2009).

The current evidence suggests that high resolution CBCT may have higher sensitivity for detection of periapical lesions than conventional radiography in laboratory studies and that this is achieved without loss of specificity. However, the results should be interpreted with caution when based on the available studies. In practice, clinical signs and symptoms add significantly to the diagnostic process and radiological evidence is not always of critical importance. Furthermore, the relatively high economic cost of CBCT compared with intraoral radiography should not be ignored. Consequently, the Panel concluded that it was not appropriate to recommend CBCT as a standard method for diagnosis of periapical inflammatory disease.

CBCT is not indicated as a standard method for identification of periapical pathosis

GP

Limited volume, high resolution CBCT may be indicated for periapical assessment, in selected cases, when conventional radiographs give a negative finding when there are contradictory positive clinical signs and symptoms

GP

Where CBCT images include the teeth, care should be taken to check for periapical disease when performing a clinical evaluation (report)

GP

4.3.4: Endodontics

Conventional endodontic imaging relies on intraoral radiography. In multi-rooted teeth and more complex cases (e.g. suspected root perforations; resorptions and atypical canal systems) intraoral radiographs at different beam angulations are used to achieve a range of perspectives and allow parallax localisation. MSCT is impracticable for dentists and hard to justify on the basis of radiation dose. Endodontic treatment requires images in three phases of management: diagnosis, during treatment (working length estimation, master cone check image) and in post-treatment review. Endodontic treatment itself includes orthograde treatment and surgical endodontic procedures.

The three-dimensional images from CBCT appear to offer a valuable new method of imaging root canal systems, and there are several non-systematic reviews in the literature that give a favourable perspective (Cotton et al 2007; Nair et al 2007; Patel et al 2007). Endodontics requires, however, a high level of image detail, and it is important to remember that available dental CBCT systems offer resolutions far lower (by approximately one order of magnitude) than those of modern intraoral radiography. Furthermore, because endodontic treatment is a single tooth procedure, CBCT systems incapable of reducing the field of view to suitable dimensions will expose areas to radiation without patient benefit.

In our previous review, we highlighted a few studies in which a superior performance of CBCT in identifying root canals was reported but in which there was no independent reference standard (Loftag-Hansen et al 2007; Low et al 2008; Matherne et al 2008). We also found that the impact of CBCT on management decisions had not been addressed in any detail, although one study on posterior teeth (Loftag-Hansen et al 2007) reported that CBCT added additional clinically relevant information in 70% of cases. We concluded that research was needed to establish objectively the diagnostic accuracy of CBCT in identifying root canal anatomy and to quantify its impact on management decisions.

Since then, several descriptive clinical studies (Neelakantan et al 2010a; Wang et al 2010; Zheng et al 2010; Zhang et al 2011) and two laboratory studies (Baratto Filho et al 2009; Neelakantan et al 2010b) have used CBCT for imaging root canal anatomy in substantial patient populations or samples. All concluded that CBCT has a role to play in identification of root canal systems, notably for the identification of presence/absence of a second mesio-buccal canal (MB2) in maxillary first molars.

In our current review, no study entirely satisfied our inclusion criteria for systematic review regarding the task of identifying root canals. One *in vitro* study (Blattner et al

2010), however, which investigated the identification of MB2 canals in maxillary first molars, provided the raw data to permit calculation of sensitivity and specificity and a decision was taken to include it in the formal review. In their small sample of teeth (n=20), sensitivity of observations using CBCT for identification of MB2 canals was 77% and specificity 83%. In a review paper, Scarfe et al (2009) reported unpublished data on the importance of the resolution of the CBCT system, suggesting that resolutions in the order of 0.12mm or less are optimal.

Because of the paucity of information about diagnostic accuracy of CBCT is assessment of root canal systems, the Panel could not support its general use for this purpose. Furthermore, the availability and use of an operating microscope may reveal root canal anatomy adequately without exposure to ionising radiation.

CBCT is not indicated as a standard method for demonstration of root canal anatomy

GP

Limited volume, high resolution CBCT may be indicated, for selected cases where conventional intraoral radiographs provide information on root canal anatomy which is equivocal or inadequate for planning treatment, most probably in multi-rooted teeth

GP

There was no literature regarding the use of CBCT during endodontic treatment or as part of post-treatment review eligible for systematic review. One laboratory study (Soğur et al, 2007) has shown that CBCT gave inferior images of the homogeneity and length of root canal fillings compared with intraoral radiographs.

On opinion-based grounds, the use of CBCT as part of planning and performing surgical endodontic procedures seems capable of justification. The literature relating to this area was very limited. Apart from case reports, one study (Rigolone et al, 2003), considered the use of CBCT for maxillary first molar teeth in the context of surgical access to the palatal root. While this was a descriptive study only, it considered the potential treatment planning value of understanding the three-dimensional relationships of anatomical structures, including the maxillary sinus. Further research is needed to consider the impact on management (surgical time, outcomes of treatment) before an evidence-based recommendation can be made.

Limited volume, high resolution CBCT may be indicated for selected cases when planning surgical endodontic procedures. The decision should be based upon potential complicating factors, such as the proximity of important anatomical structures

GP

Our previous review highlighted several case reports and case series demonstrating a value of CBCT for imaging cases of inflammatory external root resorption (Maini et al, 2008 ; Cohenca et al, 2007; Walter et al, 2008 ; Patel et al, 2007 ; Patel & Dawood, 2007) and internal resorption (Cotton et al, 2007). Our recommendation at that time gave cautious approval of a potential diagnostic role for CBCT.

Subsequently, there have been several research studies of resorptions, including four which were suitable for inclusion in the systematic review (Liedke et al 2009; Patel et al 2009b; Kamboroğlu & Kursun 2010; Durack et al 2011). Three of these were laboratory studies using drilled holes in extracted teeth, while one was a clinical study (Patel et al 2009b). Three addressed external resorption (Liedke et al 2009; Patel et al 2009b; Durack et al 2011) and two considered internal resorption (Patel et al 2009b; Kamboroğlu & Kursun 2010). The clinical study was a useful attempt to obtain *in vivo* data, but suffers from a small sample size and, most importantly, a reference standard that is based upon the index tests (consensus based on CBCT and conventional radiographic images). The laboratory external resorption models suffer from a lack of comparability with the clinical situation, where adjacent bony changes will influence detection and where resorption cavities may be different to the drilled defects prepared for the research studies.

For external resorption, the two laboratory studies (Liedke et al 2009; Durack et al 2011) suggest that CBCT provides high sensitivity and specificity for detection of artificial lesions on mandibular incisors. For artificial internal resorption lesions, Kamboroğlu & Kursun (2010) found some limitations in sensitivity and specificity for the CBCT system tested but, unfortunately, they did not involve a comparator conventional imaging method. For both types of resorption, there is some evidence that resolution of the CBCT system influences diagnostic accuracy (Liedke et al 2009; Kamboroğlu & Kursun (2010).

External resorption is sometimes idiopathic and unexpected, but there are sub-groups of patients and teeth in which there is increased risk, notably after severe dental luxation and avulsion injuries. As pointed out by Durack et al (2011) resorption may progress rapidly and early treatment is advantageous. In such cases, the use of CBCT may be justified, but the timing of the imaging is unclear. The unpredictability of the condition means that a negative finding on one occasion would not exclude resorption at a later date. Repeated CBCT examinations would be hard to justify without research evidence of its value, particularly in children. On the basis of largely laboratory evidence on limited samples, the Panel found it difficult to arrive at a recommendation with a strong evidence grade.

Internal resorption is usually identified by chance on radiographs, so it seems likely that the role of CBCT would be reserved for cases where the resorption was extensive, where perforation of the root surface was in question and where three-dimensional information could help in decision-making on extraction or retention.

Limited volume, high resolution CBCT may be indicated in selected cases of suspected, or established, inflammatory root resorption or internal resorption, where three-dimensional information is likely to alter the management or prognosis of the tooth

D

As described in our previous review, there are several other potential applications of CBCT in endodontic practice (Table 4.2).

Table 4.2: Endodontic uses of CBCT

Endodontic applications of CBCT	Reference
Differentiation of pathosis from normal anatomy	Cotton et al 2007
Relationships with important anatomical structures	Cotton et al 2007
Aiding management of dens invaginatus and aberrant pulpal anatomy	John 2008
External resorption	Siraci et al 2006 Maini et al 2008 Cohenca et al 2007 Walter et al 2008 Patel et al 2007 Patel & Dawood 2007
Internal resorption	Cotton et al 2007
Lateral root perforation by a post	Young 2007
Accessory canal identification	Cotton et al 2007 Nair et al 2007 Patel & Dawood 2007
Surgical management of fractured instrument	Tsurumachi et al 2007
Aiding surgical endodontic planning	Patel et al 2007 Patel & Dawood 2007

It seems likely from these case reports and non-systematic reviews that CBCT will have several valuable applications in *selected* cases. The absence of high quality studies available for this systematic review underlines the need for further research in this important area of dental practice.

Limited volume, high resolution CBCT may be justifiable for selected cases, where endodontic treatment is complicated by concurrent factors, such as resorption lesions, combined periodontal/endodontic lesions, perforations and atypical pulp anatomy

C

4.3.5: Dental trauma

Trauma to teeth is a fairly common event faced by dentists in clinical practice. As described in our previous review, case reports and non-systematic reviews have included comments about the potential role of CBCT in assessment of dental injuries, as shown below:

Table 4.3: CBCT in dental trauma

Application of CBCT for dento-alveolar trauma	Reference
Root fractures	Terakado et al 2000 Cohenca et al 2007a Cotton et al 2007 Nair et al 2007 Patel & Dawood 2007
Luxation injuries	Cohenca et al 2007a Patel et al 2007
Avulsion	Walter & Krastl 2008
Root resorption as a post-trauma complication	Cohenca et al 2007b Walter et al 2008

Unlike our previous review, on this occasion we were able to identify eight publications for the systematic review on the detection of root fractures using CBCT (Hassan et al 2009; Iikubo et al 2009; Wenzel et al 2009; Hassan et al 2010; Kamboroglu et al 2010; Melo et al 2010; Ozer 2010; Varshozaz et al 2010), seven of which were laboratory studies using extracted teeth and the other an *in vivo* animal study (Iikubo et al 2009). Some studies included root-filled teeth, while others did not. The study of Mora et al (2007) was not included in the review because it did not use a commercially available CBCT system, while that of Bernardes et al (2009) was excluded because it did not report diagnostic accuracy. All studies in which a comparison was made report significantly higher diagnostic accuracy for CBCT compared with conventional radiography, although “low” resolution scans (possibly around 0.3mm or larger voxel dimensions) may not offer this diagnostic advantage (Wenzel et al 2009; Hassan et al 2010; Kamboroglu et al 2010). The presence of root fillings in teeth may reduce specificity (increased false positive diagnoses) by artefact (Hassan et al 2010). Melo et al (2010) assessed diagnostic accuracy in the presence of root fillings without a comparison with conventional radiography and also reported problems with specificity. These workers also examined teeth containing metal posts; they found a lower sensitivity and specificity than for teeth with fractures but without posts. They also reported significantly inferior diagnostic performance when 0.3mm voxels were used, compared with 0.2mm voxels.

In practice, patients with suspected root fracture fall into two broad categories. First, there are those with acute trauma to anterior teeth, often children. Secondly, there are patients whose teeth may have fractured due to chronic trauma during normal function, usually in endodontically treated teeth. In the first group, the acute injuries may mean CBCT is not feasible due to treatment priorities and the problems associated with traumatised children of immobilisation for the scan. In such cases, it would seem reasonable to limit the radiological examination to simple radiographs and use CBCT at a later date if the conventional radiographs provide inadequate information for managing the patient. In the second group, the weight of evidence suggests that root fillings and posts limit diagnostic accuracy. Of course, in some of these cases diagnosis can be made, and prognosis assessed, on clinical examination evidence alone, so imaging may not always be indicated. In other cases conventional radiography may provide sufficient information for management.

Limited volume, high resolution CBCT is indicated in the assessment of dental trauma (suspected root fracture) in selected cases, where conventional intraoral radiographs provide inadequate information for treatment planning

B

The role of CBCT in more significant trauma is considered under “Surgical applications”, below.

4.3.6: References

Akdeniz BG, Gröndahl HG, Magnusson B. Accuracy of proximal caries depth measurements: comparison between limited cone beam computed tomography, storage phosphor and film radiography. *Caries Res* 2006; 40: 202-207.

Baratto Filho F, Zaitter S, Haragushiku GA, de Campos EA, Abuabara A, Correr GM. Analysis of the internal anatomy of maxillary first molars by using different methods." *J Endod* 2009; 35: 337-342.

Bernardes RA, deMoraes IG, Húngaro Duarte MA, Azevedo BC, de Azevedo JD, Bramante CM. Use of cone beam volumetric tomography in the diagnosis of root fractures. *Oral Surg Oral Med Oral Pathol Oral Radiol Endod* 2009; 108: 270-277.

Bhatavadekar NB, Paquette DW. Long-term follow-up and tomographic assessment of an intrabony defect treated with enamel matrix derivative. *J Periodontol* 2008; 79: 1802-1808.

Blattner TC, George N, Lee CC, Kumar V, Yelton CDJ. Efficacy of cone-beam computed tomography as a modality to accurately identify the presence of second mesiobuccal canals in maxillary first and second molars: a pilot study. *J Endod* 2010; 36: 867–870

Christiansen R, Kirkevang LL, Gotfredsen E, Wenzel A. Periapical radiography and cone beam computed tomography for assessment of the periapical bone defect 1 week and 12 months after root-end resection. *Dentomaxillofac Radiol* 2009; 38: 531-536.

- Cohenca N, Simon JH, Mathur A, Malfaz JM. Clinical indications for digital imaging in dento-alveolar trauma. Part 1: traumatic injuries." *Dental Traumatol* 2007a; 23: 95-104.
- Cohenca NJH, Simon JH, Mathur A, Malfaz JM. Clinical indications for digital imaging in dento-alveolar trauma. Part 2: root resorption. *Dent Traumatol* 2007b; 23: 105-113.
- Cotton TP, Geisler TM, Holden DT, Schwartz SA, Schindler WG. Endodontic applications of cone-beam volumetric tomography. *J Endod* 2007; 33: 1121-1132.
- De Paula-Silva FWG, Wu M-K, Leonardo MR, da Silva SA, Wesselink PR. Accuracy of periapical radiography and cone-beam computed tomography scans in diagnosing apical periodontitis using histopathological findings as a gold standard. *J Endod* 2009; 35: 1009-1012.
- Durack C, Patel S, Davies J, Wilson R, Mannocci F. Diagnostic accuracy of small volume cone beam computed tomography and intraoral periapical radiography for the detection of simulated external inflammatory root resorption. *Int Endod J* 2011; 44: 136-147.
- Estrela C, Reis Bueno M, Rodrigues Leles C, Azavedo B, Ribamar Azevedo J. Accuracy of cone beam computed tomography and panoramic and periapical radiography for detection of apical periodontitis. *J Endod* 2008a; 34: 273-279.
- Estrela C, Reis Bueno M, Azevedo BC, Azevedo JR, Pecora JD. A new periapical index based on cone beam computed tomography. *J Endod* 2008b; 34: 1325-1331.
- European Commission. Radiation Protection 136. European Guidelines on Radiation Protection in Dental Radiology. Luxembourg: Office for Official Publications of the European Communities, 2004. Available from: http://ec.europa.eu/energy/nuclear/radioprotection/publication/doc/136_en.pdf
- Haiter-Neto F, Wenzel A, Gottfredsen E. Diagnostic accuracy of cone beam computed tomography scans compared with intraoral image modalities for detection of caries lesions. *Dentomaxillofac Radiol* 2008; 37: 18-22.
- Hannig C, Krieger E, Dullin C, Merten H-A, Attin T, Grabbe E, Heidrich G. Volumetry of human molars with flat panel-based volume CT in vitro. *Clin Oral Invest* 2006; 10: 253-257.
- Hassan B, Metska ME, Ozok AR, van der Stelt P, Wesselink PR. Detection of vertical root fractures in endodontically treated teeth by a cone beam computed tomography scan. *J Endod* 2009; 35: 719-722.
- Hassan B, Metska ME, Ozok AR, van der Stelt P, Wesselink PR.. Comparison of five cone beam computed tomography systems for the detection of vertical root fractures *J Endod* 2010; 36:126-129.
- Iikubo M, Kobayashi K, Mishima A, Shimoda S, Daimaruya T, Igarashi C, Imanaka M, Yuasa M, Sakamoto M, Sasano T. Accuracy of intraoral radiography, multidetector helical CT, and limited cone-beam CT for the detection of horizontal tooth root fracture. *Oral Surg Oral Med Oral Pathol Oral Radiol Endod.* 2009; 108: e70-74.
- Ito K, Yoshinuma N, Goke E, Arai Y, Shinoda K. Clinical application of a new compact computed tomography system for evaluating the outcome of regenerative therapy: a case report. *J Periodontol* 2001; 72: 696-702.
- John V. Non-surgical management of infected type III dens invaginatus with vital surrounding pulp using contemporary endodontic techniques. *Aust Endod J* 2008; 34: 4-11.
- Kamboroğlu K, Kurt H, Kolsuz E, Öztaş B, Tatar İ, Çelik HH. Occlusal caries depth measurements obtained by five different imaging modalities. *J Digit Imaging* 2010a; Nov 30 [Epub ahead of print].
- Kamboroğlu K, Murat S, Yüksel SP, Cebeci ARÍ, Paksoy CS. Occlusal caries detection by using a cone-beam CT with different voxel resolutions and a digital intraoral sensor. *Oral Surg Oral Med Oral Pathol Oral Radiol Endod* 2010b; 109: e63-e69.

Kamburoğlu K, Murat S, Yüksel SP, Cebeci AR, Paksoy CS. Detection of vertical root fracture using cone-beam computerized tomography: an in vitro assessment. *Oral Surg Oral Med Oral Pathol Oral Radiol Endod.* 2010c;109: e63-69.

Kamburoğlu K, Kursun S. A comparison of the diagnostic accuracy of CBCT images of different voxel resolutions used to detect simulated small internal resorption cavities. *Int Endod J* 2010; 43: 798-807.

Kasaj A, Willershausen B. (2007). Digital volume tomography for diagnostics in periodontology. *Int J Comput Dent* 2007; 10: 155-168.

Kayıpmaz S, Sezgin ÖS, Sarıcaoğlu ST, Çan G. An in vitro comparison of diagnostic abilities of conventional radiography, storage phosphor, and cone beam computed tomography to determine occlusal and approximal caries. *Eur J Radiol* 2010; Oct 7 [Epub ahead of print].

Liedke GS, da Silveira HE, da Silveira HL, Dutra V, de Figueiredo JA. Influence of voxel size in the diagnostic ability of cone beam tomography to evaluate simulated external root resorption. *J Endod* 2009; 35: 233-235.

Loftag-Hansen S, Huumonen S, Gröndahl K, Gröndahl H-G. Limited cone-beam CT and intraoral radiography for the diagnosis of periapical pathology. *Oral Surg Oral Med Oral Pathol Oral Radiol Endod* 2007; 103:114-119.

Low KMT, Dula K, Bürgin W, von Arx, T. Comparison of periapical radiography and limited cone-beam tomography in posterior maxillary teeth referred for apical surgery. *J Endod* 2008; 34: 557-562.

Maini AP, Durning P, Drage N. Resorption: within or without? The benefit of cone-beam computed tomography when diagnosing a case of an internal/external resorption defect. *Br Dent J* 2008; 204: 135-137.

Matherne RP, Angelopoulos C, Kulild JC. Use of cone-beam computed tomography to identify root canal systems in vitro. *J Endod* 2008; 34: 87-89.

Melo SL, Bortoluzzi EA, Abreu M Jr, Corrêa LR, Corrêa M. Diagnostic ability of a cone-beam computed tomography scan to assess longitudinal root fractures in prosthetically treated teeth. *J Endod.* 2010; 36:1879-1882.

Mengel R, Candir M, Siratori, K, Flores-de-Jacoby L. Digital volume tomography in the diagnosis of periodontal defects: an in vitro study on native pig and human mandibles. *J Periodontol* 2005; 76: 665-673.

Misch KA, Yi ES, Sarment DP. Accuracy of cone beam computed tomography for periodontal defect measurements. *J Periodontol* 2006; 77: 1261-1266.

Mol A, Balasundaram A. In vitro cone beam computed tomography imaging of periodontal bone. *Dentomaxillofac Radiol* 2008; 37: 319-324.

Mora MA, Mol A, Tyndall DA, Rivera EM. In vitro assessment of local computed tomography for the detection of longitudinal tooth fractures. *Oral Surg Oral Med Oral Pathol Oral Radiol Endod* 2007;103: 825-829.

Nair MK, Nair UP. Digital and advanced imaging in endodontics: a review. *J Endod* 2007; 33: 1-6.

Naitoh M, Yamada S, Noguchi T, Arijii E, Nagao J, Mori K, Kitasaka T, Suenaga Y. Three-dimensional display with quantitative analysis in alveolar bone resorption using cone-beam computerized tomography for dental use: a preliminary study. *Int J Periodontics Restorative Dent* 2006; 26: 607-612.

Nakata K, Naiyoh M, Izumi M, Inamoto K, Arijii E, Nakamura, H. Effectiveness of dental computed tomography in diagnostic imaging of periradicular lesion of each root of a multirrooted tooth: a case report. *J Endod* 2006; 32: 583-587.

Neelakantan P, Subbarao C, Ahuja R, Subbarao CV, Gutmann JL. Cone-Beam Computed Tomography Study of Root and Canal Morphology of Maxillary First and Second Molars in an Indian Population. *J Endod* 2010a; 36: 1622-1627.

Neelakantan P, Subbarao C, Subbarao CV Comparative Evaluation of Modified Canal Staining and Clearing Technique, Cone-Beam Computed Tomography, Peripheral Quantitative Computed Tomography, Spiral Computed Tomography, and Plain and Contrast Medium-enhanced Digital Radiography in Studying Root Canal Morphology. *J Endod* 2010b; 36: 1547-1551.

Noujeim M, Prihoda TJ, Langlais R, Nummikoski P. Evaluation of high-resolution cone beam computed tomography in the detection of simulated inter-radicular bone lesions. *Dentomaxillofac Radiol* 2009; 38: 156-162.

Özen T, Kamburoğlu K, Cebeci ARI, Yuskel SP, Paksoy C. Interpretation of chemically created periapical lesions using 2 different dental cone-beam computerized tomography units, an intraoral digital sensor, and conventional film. *Oral Surg Oral Med Oral Pathol Oral Radiol Endod* 2009; 107: 426-432.

Özer SY. Detection of vertical root fractures of different thicknesses in endodontically enlarged teeth by cone beam computed tomography versus digital radiography. *J Endod* 2010; 36: 1245–1249.

Patel S, Dawood A. The use of cone beam computed tomography in the management of external cervical resorption lesions. *Int Endod J* 2007; 40: 730-737.

Patel S, Dawood A, Mannocci F, Wilson R, Pitt Ford T. Detection of periapical bone defects in human jaws using cone beam computed tomography and intraoral radiography. *Int Endod J* 2009a; 42: 507-515.

Patel S, Dawood A, Pitt Ford T, Whaites E. The potential applications of cone beam computed tomography in the management of endodontic problems. *Int Endod J* 2007; 40: 818-830.

Patel S, Dawood A, Wilson R, Horner K, Mannocci F. The detection and management of root resorption lesions using intraoral radiography and cone beam computed tomography - an *in vivo* investigation. *Int Endod J* 2009b; 42: 831-838.

Pinsky HM, Dyda S, Pinsky RW, Misch KA, Sarment DP. Accuracy of three-dimensional measurements using cone-beam CT. *Dentomaxillofac Radiol* 2006; 35: 410-416.

Qu X, Li G, Zhang Z, Ma X. Detection accuracy of *in vitro* approximal caries by cone beam computed tomography images. *Eur J Radiol* 2010; Feb 23. [Epub ahead of print]

Rigolone M, Pasqualini D, Bianchi L, Berutti E, Bianchi SD. Vestibular surgical access to the palatine root of the superior first molar: "low dose cone-beam" CT analysis of the pathway and its anatomic variations. *J Endod* 2003; 29: 773-775.

Scarfe WC, Levin MD, Gane D, Farman AG. Use of cone beam computed tomography in endodontics. *Int J Dent* 2009; 2009:634567. Epub 2010 Mar 31.

Şenel B, Kamburoğlu K, Üçok Ö, Yüksel SP, Özen T, Avsever H. Diagnostic accuracy of different imaging modalities in detection of proximal caries. *Dentomaxillofac Radiol* 2010; 39: 501-511.

Siraci E, Cem Gungor H, Taner B, Cehreli ZC. Buccal and palatal talon cusps with pulp extensions on a supernumerary primary tooth. *Dentomaxillofac Radiol* 2006; 35: 469-472.

Soğur E, Baksi BG, Gröndahl H-G. Imaging of root canal fillings: a comparison of subjective image quality between limited cone-beam CT, storage phosphor and film radiography. *Int Endod J* 2007; 40: 179-185.

- Soğur E, Baksi BG, Gröndahl H-G, Lomcali G, Sen BH. Detectability of chemically induced periapical lesions by limited cone beam computed tomography, intra-oral digital and conventional film radiography. *Dentomaxillofac Radiol* 2009; 38: 458-464.
- Stavropoulos A, Wenzel A. Accuracy of cone beam dental CT, intraoral digital and conventional film radiography for the detection of periapical lesions. An ex vivo study in pig jaws. *Clin Oral Invest* 2007; 11: 101-106.
- Takane M, Sato S, Suzuki K, Fukuda T, Asano Y, Honda K, Arai Y, Ito K. Clinical application of cone beam computed tomography for ideal absorbable membrane placement in interproximal bone defects. *J Oral Sci.* 2010; 52: 63-69.
- Terakado M, Hashimoto K, Arai Y, Honda M, Sekiwa T, Sato H. Diagnostic imaging with newly developed ortho cubic super-high resolution computed tomography (Ortho-CT). *Oral Surg Oral Med Oral Pathol Oral Radiol Endod* 2000; 89: 509-518.
- Tsuchida R, Araki K, Okano T. Evaluation of a limited cone-beam volumetric imaging system: comparison with film radiography in detecting incipient proximal caries. *Oral Surg Oral Med Oral Pathol Oral Radiol Endod* 2007; 104: 412-416.
- Tsurumachi T, Honda K. A new cone beam computerized tomography system for use in endodontic surgery. *Int Endod J* 2007; 40: 224-232.
- Vandenbergh B, Jacobs R, Yang J. Diagnostic validity (or acuity) of 2D CCD versus 3D CBCT-images for assessing periodontal breakdown. *Oral Surg Oral Med Oral Pathol Oral Radiol Endod* 2007; 104: 395-401.
- Vandenbergh B, Jacobs R, Yang J. Detection of periodontal bone loss using digital intraoral and cone beam computed tomography images: an in vitro assessment of bony and/or infrabony defects. *Dentomaxillofac Radiol* 2008; 37: 252-260.
- Varshosaz M, Tavakoli MA, Mostafavi M, Baghban AA. Comparison of conventional radiography with cone beam computed tomography for detection of vertical root fractures: an in vitro study. *J Oral Sci* 2010; 52: 593-597.
- Walter, C, Krastl G, Izquierdo A, Hecker H, Weiger R. Replantation of three avulsed permanent incisors with complicated crown fractures. *Int Endod J* 2008; 41: 356-364.
- Walter C, Weiger R, Zitzmann NU. Accuracy of three-dimensional imaging in assessing maxillary molar furcation involvement. *J Clin Periodontol* 2010; 37: 436-441.
- Wang Y, Zheng QH, Zhou XD, Tang L, Wang Q, Zheng GN, Huang DM. Evaluation of the root and canal morphology of mandibular first permanent molars in a western Chinese population by cone-beam computed tomography. *J Endod* 2010; 36: 1786-1789.
- Wenzel A, Haiter-Neto F, Frydenberg M, Kirkevang LL. Variable-resolution cone-beam computerized tomography with enhancement filtration compared with intraoral photostimulable phosphor radiography in detection of transverse root fractures in an in vitro model. *Oral Surg Oral Med Oral Pathol Oral Radiol Endod.* 2009;108: 939-945.
- Young GR. Contemporary management of lateral root perforation diagnosed with the aid of dental computed tomography. *Aust Endod J* 2007; 33: 112-118.
- Young SM, Lee JT, Hodges RJ, Chang T-L, Elashoff DA,, White SC. A comparative study of high-resolution cone beam computed tomography and charge-coupled device sensors for detecting caries. *Dentomaxillofac Radiol* 2009; 38: 445-451.
- Zhang Z, Qu X, Li G, Zhang Z, Ma X. The detection accuracies for proximal caries by cone-beam computerized tomography, film, and phosphor plates. *Oral Surg Oral Med Oral Pathol Oral Radiol Endod* 2011; 111:103-108

Zhang R, Yang H, Yu X, Wang H, Hu T, Dummer PM. Use of CBCT to identify the morphology of maxillary permanent molar teeth in a Chinese subpopulation. *Int Endod J* 2011; 44:162-169.

Zheng QH, Wang Y, Zhou XD, Wang Q, Zheng GN, Huang DM. Evaluation of the root and canal morphology of mandibular first permanent molars in a Chinese population. *J Endod* 2010; 36: 1480-1484.

4.4 Surgical applications

Surgery of the dental and maxillofacial region encompasses minor procedures (oral surgery) that may be performed in dental practices and major surgery (maxillofacial surgery) that would always be carried out by specialists, often in a hospital environment.

4.4.1 Exodontia

There is no literature related to the use of CBCT as part of the pre-extraction assessment of erupted teeth and there seems no good reason to suggest its use for this purpose. The literature concentrates on unerupted teeth, principally lower third molars, as demonstrated in the systematic review performed by Guerrero et al (2011).

A number of clinical studies, case series and non-systematic reviews have been published on the use of CBCT for pre-surgical assessment of impacted third molars including Heurich et al (2002), Nakagawa et al (2002), Danforth et al (2003), Nakagawa et al (2007), Friedland et al (2008), Neugebauer et al (2008), Nakayama et al (2009), Tantanapornkul et al (2009), Lübbers et al (2010), Suomalainen et al (2010) and Yamada et al (2011). The broad conclusion of reviewing these studies is that CBCT may offer advantages for the surgeon in showing the anatomical position and relationships of mandibular third molars where there is a close inter-relationship between the third molar root and the mandibular canal (inferior dental canal), but that CBCT should not be used routinely for all third molar pre-surgical assessments.

Two studies satisfied the inclusion criteria for the review of diagnostic accuracy (Tantanapornkul et al 2007; Ghaeminia et al 2009), both of which considered the relationship between the mandibular third molar root and the mandibular canal and a reference standard of intra-surgical direct visualisation. Cone-beam CT was significantly superior to panoramic images in predicting neurovascular bundle exposure during extraction of impacted mandibular third molar teeth, with impressive sensitivity (Tantanapornkul et al 2007). The more recent study by Ghaeminia et al (2009), however, provided apparently contradictory findings. They found no significant difference in sensitivity and specificity between panoramic radiography and CBCT in predicting exposure of the mandibular canal. The difference in results of the two studies probably reflects different case selection. Direct exposure of the canal during surgery is, however, not a prerequisite for post-operative nerve damage. Injury may occur by pressure effects through thin intervening bone. As pointed out by Ghaeminia et al (2009), CBCT offers the advantage of identifying bucco-lingual position of the canal. Other factors, such as complex root morphology, may also favour the use of a cross-sectional imaging technique.

Despite the apparent contradiction in the results of the systematically reviewed papers (Tantanapornkul et al 2007; Ghaeminia et al 2009), the weight of evidence from the wider literature is such that the Panel confirmed the broad intent of the recommendation made in the previous guidelines, but with a modification of the wording and a reduction in the evidence grade. The strategy for imaging presented by Flygare & Ohman (2008), in which CBCT is reserved for cases in which conventional imaging does not adequately depict the nerve/ tooth relationship, is in agreement with our recommendation. An exception foreseen to this may be where the favoured practice is to perform third molar coronectomy rather than complete tooth removal when there is a close mandibular canal/ third molar root relationship. If the decision to perform coronectomy can be made on the basis of conventional radiography, then CBCT is redundant.

Where conventional radiographs suggest a direct inter-relationship between a mandibular third molar and the mandibular canal, and when a decision to perform surgical removal has been made, CBCT may be indicated

C

It is important to ensure that the above recommendation does not lead to a “drift” towards routine use. The incidence of post-surgical dysaesthesia after third molar removal is very low in the hands of experienced surgeons and there is no evidence of improved outcomes through the use of CBCT. By “direct inter-relationship”, the Panel intended to highlight the features on conventional radiographs which are related to postoperative dysaesthesia: “darkening” of the root, interruption of the canal wall and diversion of the canal (Rood & Shehab 1990). Each case must be judged on an individualised assessment of risk.

The literature on surgical removal of other tooth types is very small, although some of the orthodontic literature related to impacted maxillary canines is also relevant here (see Section 4.2.1). It seems likely that CBCT may have a role in pre-surgical assessment of any unerupted tooth where conventional radiographs (intraoral and panoramic) fail to give the information required. The Panel agreed that it was important to emphasise the need to use the smallest field of view consistent with the information required, consistent with the Basic Principle No.9 (Section 3).

CBCT may be indicated for pre-surgical assessment of an unerupted tooth in selected cases where conventional radiographs fail to provide the information required

GP

4.4.2 Implant dentistry

In investigating an implant site, a surgeon requires information on bone volume and quality, topography and the relationship to important anatomical structures, such as nerves, vessels, roots, nasal floor, and sinus cavities (Harris et al 2002).

In 2002, a Working Group of the European Association of Osseointegration (EAO) devised consensus guidelines on imaging for implant dentistry (Harris et al 2002). They did not include any comment on CBCT. They did, however, describe criteria for use of “cross-sectional imaging” (at that time, spiral tomography and MSCT).

The EAO guidelines made the following key points:

- Clinicians should decide if a patient requires cross-sectional imaging on the basis of the clinical examination, the treatment requirements and on information obtained from conventional radiographs.
- The technique chosen should provide the required diagnostic information with the least radiation exposure to the patient.
- “Standard” imaging modalities are combinations of conventional radiographs.
- Cross-sectional imaging is applied to those cases where more information is required after appropriate clinical examination and standard radiographic techniques have been performed.

The EAO guidelines presented valuable information on the special clinical situations in implant dentistry when cross-sectional imaging is required (Table 4.4). The guidelines go on to explain that cross-sectional imaging is of principal value in pre-operative assessment and treatment planning, but that it is not part of a “routine protocol” for post-operative examinations “unless there is a need for assessments in situations where some kind of complications have occurred, such as nerve damage, postoperative infections in relation to nasal and/or sinus cavities close to implants” (Harris et al 2002).

While these criteria for cross-sectional imaging are subjective in nature, relying heavily on subjective “clinical doubt”, they do offer useful guidance. The Panel had neither the remit nor the expertise to reconsider the EAO guidelines. The primary question for clinicians is whether or not cross-sectional imaging is required for implant planning, rather than whether CBCT is required. Nonetheless, CBCT has different radiation dose implications and different capabilities. Consequently, in 2009 the Panel recommended that the EAO reviewed its 2002 consensus guidelines on the use of imaging in implant dentistry to take into account the availability of CBCT. The EAO are currently undertaking this review.

There is a substantial literature related to the use of CBCT in dental implantology. Implant treatment planning has been the most frequent use of MSCT in dentistry. Nonetheless, there were no studies identified for inclusion in the systematic review on diagnostic accuracy, which was not altogether surprising. Studies on geometric accuracy for linear measurements, however, are of obvious importance in implant planning; these show high accuracy (see Section 4.1.1). Overall, the evidence suggests that CBCT has sufficient geometric accuracy for linear measurements in implant dentistry. Interestingly, however, one study compared ridge mapping with CBCT, using a direct surgical measurement as a reference standard, and found that

CBCT was less consistent than ridge mapping and that it did not add any additional information (Chen et al 2008). Furthermore, as pointed out in Section 4.1.1, accuracies reported in laboratory studies may be not as good in patients due to minor movement during scanning. As such, the Panel agreed that clinicians should use their clinical judgement and a margin of safety when planning implants close to important anatomical structures. Apart from geometric accuracy, an important aspect is the ease of visualisation of important structures on CBCT. Loubele et al 2007 demonstrated better subjective image quality for important structures for CBCT compared with MSCT. Mengel et al (2006) showed promising results for visualisation of peri-implant defects in an animal study. CBCT resolution may, however, be important in the efficacy of visualising fine detail of cortical bone thickness (Razavi et al 2010).

Table 4.4: Special indications for cross-sectional imaging (adapted from Fig. 2b in Harris et al 2002).

Maxilla	Single tooth	a. incisive canal b. descent of maxillary sinus c. clinical doubt about shape of alveolar ridge
	Partially dentate	a. descent of maxillary sinus b. clinical doubt about shape of alveolar ridge
	Edentulous	a. descent of maxillary sinus b. clinical doubt about shape of alveolar ridge
Mandible	Single tooth	a. clinical doubt about position of mandibular canal b. clinical doubt about shape of alveolar ridge
	Partially dentate	a. clinical doubt about position of mandibular canal or mental foramen b. clinical doubt about shape of alveolar ridge
	Edentulous	a. severe resorption b. clinical doubt about shape of alveolar ridge c. clinical doubt about position of mandibular canal if posterior implants are to be placed

Much research interest has focused on the ability of CBCT to image neurovascular structures in the jaws, with several descriptive studies and case series being reported (Angelopoulos et al 2008; Pires et al 2009; Uchida et al 2009; Makris et al 2010; Naitoh et al 2010). This work is set in the context of the risk of haemorrhage during surgery, particularly in the floor of the mouth where the consequences can be severe, and on post-surgical neuropathy. The Panel recognise that this risk is of significance to patient outcome and well-being. Naitoh et al (2010) concluded that there was no significant difference between CBCT and MSCT for the depiction of fine anatomical features in the mandible associated with neurovascular structures, although their results may not be applicable to the wide range of CBCT and MSCT systems, exposure protocols and other variables influencing image quality.

The EAO guidelines emphasise the importance of relating accurately the image data to the surgical situation: *“The diagnostic information can be enhanced by the use of appropriate radiopaque markers or restorative templates. However, this information cannot be transferred exactly to the surgical site as long as no intraoperative*

navigation is used" (Harris et al 2002). Several papers have been published relating to the accuracy of implant placement using surgical guides manufactured using CBCT datasets (Fortin et al 2002; Fortin et al 2003; Sarment et al 2003; van Steenberghe et al 2003; Nickenig & Eitner 2007; van Assche et al 2007; Nickenig & Eitner 2010; Arisan et al 2010; van Assche et al 2010; Al-Ekrish & Ekram, 2011). These studies suggest that, within specified limits of error, CBCT is an effective means of providing data for the manufacture of surgical guides in implant dentistry.

There are a large number of publications (case studies; non-systematic reviews; descriptive studies) that illustrate the use of CBCT in implant dentistry. Many of these were consulted during the review by members of the Panel to help build the body of knowledge in developing the guidelines (Almog et al 2006; Arisan et al 2010; Blake et al 2008; Bousquet & Joyard 2008; Fan et al 2008; Ganz 2005; Ganz 2006; Ganz 2008; Ganz 2010; Garg 2007; Guerrero et al 2006; Hatcher et al 2003; Moore 2005; Peck & Conte 2008; Sato et al 2004). These publications make it clear that CBCT is being used widely for implant dentistry. As such, The Panel makes the following recommendations:

CBCT is indicated for cross-sectional imaging prior to implant placement as an alternative to existing cross-sectional techniques where the radiation dose of CBCT is shown to be lower

D

For cross-sectional imaging prior to implant placement, the advantage of CBCT with adjustable fields of view, compared with MSCT, becomes greater where the region of interest is a localised part of the jaws, as a similar sized field of view can be used

GP

While the emphasis has been on assessment of bone quantity, there is interest in "bone quality" assessment using CBCT. Bone density evaluation of implant sites is feasible using MSCT (de Oliveira et al 2008). Since Barone et al (2003), a number of studies have, however, tried to derive Hounsfield Units (HUs) from CBCT. Some studies suggest this is potentially feasible, with moderate or good correlations between CBCT-derived HUs and density data from other sources (Aranyarachkul et al 2005; Lagravère et al 2006; Lagravère et al 2008; Mah et al 2010; Nomura et al 2010). Song et al (2009) reported strong correlations between CT numbers and implant primary stability. Lee et al (2007), however, found only moderate correlations between drilling resistance torque and HU values. Bryant et al (2008) showed substantial changes in HU values of a region were produced in an iCAT scanner depending on the axial position in the slice due to the effect of the mass of material within and outside the scan volume. Recently, Nackaerts et al (2011) compared MSCT and

CBCT scanners and reported that intensity values in CBCT images were not reliable, because the values are influenced by the scanner device, the imaging parameters and the positioning of the field of view. It is clear from this work that there is uncertainty regarding the use of CBCT to derive HU or other “density” measures of bone and that it cannot be recommended for this purpose in everyday practice.

4.4.3 Bony pathosis

Occasionally, a dentist may be presented with a patient with an unusual bony lesion. Cysts, tumours and a wide range of esoteric lesions can present in the jaws causing symptoms and/or clinical signs; some may only be detected by chance on conventional radiography. There are numerous case reports of bony lesions that have been imaged using CBCT (Abdelkarim et al 2008; Araki et al 2006; Araki et al 2007; Barragan-Adjemian et al 2009; Closmann & Schmidt 2007; Fullmer et al 2007; Guttenberg 2008; Harokopakis-Hajishengallis & Tiwana 2007; Kamel et al. 2009; Kumar et al 2007; Nakagawa et al 2002; Quereshy et al 2008; Rodrigues & Estrela 2008; Rozylo-Kalinowska & Rozylo 2001; Scherer et al 2008; Schulze et al 2006; Schulze 2009; Smith et al 2007; Ziegler et al 2002). While these are too wide ranging in pathoses and are case reports/series rather than formal studies, it seems reasonable to predict that CBCT will have a useful role in the assessment of bony pathosis of the jaws.

Four studies falling into this clinical category were reviewed formally by the Panel in the context of diagnostic accuracy (Hendrikx et al 2010; Momin et al 2009; Rosenberg et al 2010; Simon et al 2006). Momin et al (2009) measured the diagnostic accuracy of high resolution cone-beam CT compared with panoramic radiography in the assessment of mandibular invasion by gingival carcinoma, validated by histopathological findings after surgery. They found high sensitivity of diagnosis based on CBCT, although specificity was only similar to panoramic radiography. They also noted the challenge of restoration-related artefacts and false positives from periodontal disease. Hendrikx et al (2010) reported higher sensitivity and specificity for CBCT in detecting mandibular invasion by carcinoma, validated by histopathology, compared with both panoramic radiography and MR, although their results were not statistically significant due to sample size. The results of these studies are promising and further research is needed to investigate the role of CBCT in management of patients with oral carcinoma.

The Panel considered that in cases of oral carcinoma, other cross-sectional imaging (MSCT, MR) would be performed first as part of diagnostic work-up, as was the case in the study of Hendrikx et al (2010). The Panel concluded that, on the basis of current research, the role for CBCT was likely to be in cases where these imaging techniques could not confirm or refute bony involvement and where the diagnosis of bone involvement would change a treatment plan. As such, the Panel maintain the guideline established as a Basic Principle (Section 3).

Where it is likely that evaluation of soft tissues will be required as part of the patient's radiological assessment, the appropriate initial imaging should be MSCT or MR, rather than CBCT

BP

Limited volume, high resolution, CBCT may be indicated for evaluation of bony invasion of the jaws by oral carcinoma when the initial imaging modality used for diagnosis and staging (MR or MSCT) does not provide satisfactory information

D

The studies of Simon et al (2006) and Rosenberg et al (2010) both considered whether CBCT could be used to differentiate cysts from apical granulomas. Although Simon et al (2006) suggested that “CBCT may provide a more accurate diagnosis than biopsy and histology”, analysis of their results by the Panel indicated that CBCT had high sensitivity for diagnosis of cysts but limited specificity (i.e. over-diagnosis of cysts). The work of Rosenberg et al (2010) found poor accuracy for CBCT in differentiating cysts from granulomas and they concluded that CBCT was not a reliable diagnostic method.

In the context of bony pathosis generally, the Panel felt that it was important that unless dentists are treating patients themselves (as opposed to referral to an oral surgeon) it is probably correct to leave the choice of imaging to the surgeon who intends to treat the patient.

4.4.4 Facial trauma

The management of significant maxillofacial trauma is outside the normal working practice of a dentist and limited to specialist/ hospital practice. Fractures are conventionally imaged using plain radiography or MSCT, depending on custom and practice. Generally speaking, as stated by Schoen et al (2008), “when radiographs do not show clearly the degree of displacement, type of fracture or degree of comminution, for example, in suspected fractures of the condylar head, CT or cone-beam CT is indicated”. The potential role of CBCT in assessment of maxillofacial fractures has been reviewed by Shintaku et al (2009).

One study was identified as suitable for formal systematic review (Sirin et al 2010) although this study was performed in an *ex vivo* animal model. This reported no

significant difference between CT and CBCT in condylar fracture detection. Several case studies/ case series were identified that demonstrated the effective use of CBCT for orbital floor fractures (Zizelmann et al 2007; Drage & Sivarajasingam 2008), nasal bone fractures (Bremke et al 2009), mandibular fracture (Ziegler et al 2002), intraoperative imaging of fractures of the mandible (Heiland et al 2004a; Scarfe 2005; Pohlenz et al 2007; Pohlenz et al 2008) and zygomatic fractures (Heiland et al 2004a; Heiland et al 2007; Pohlenz et al 2007), postoperative imaging of zygomatic fractures (Heiland et al 2004b) and unfavourable splits during bilateral sagittal split osteotomy (Lloyd et al 2011). The Panel felt that there was a need for further diagnostic accuracy studies of CBCT for the common fracture types (mandibular and maxillary). Consequently, a low grading for the following recommendation was applied:

For maxillofacial fracture assessment, where cross-sectional imaging is judged to be necessary, CBCT may be indicated as an alternative imaging modality to MSCT where radiation dose is shown to be lower and soft tissue detail is not required

D

In foreign body detection and localization, CBCT is suitable for imaging high attenuation materials but not as effective as MSCT for lower attenuation objects (Eggers et al 2007; Stuehmer et al 2008).

4.4.5 Orthognathic surgery

This application is closely allied to orthodontics and the evidence presented in Section 4.1.1 regarding measurement accuracy is also relevant here. Whereas in Section 4.2.2 the Panel did not support the routine use of CBCT for orthodontic assessment, the patients likely to be candidates for orthognathic surgery (with significant facial deformity) are more likely to benefit from cross-sectional imaging.

There is a large literature relating to the use of three-dimensional imaging in orthognathic surgery, including reviews by Caloss et al (2007), Edwards (2010), and Popat et al (2010). Some additional papers were reviewed under this heading (Enciso et al 2003; Cevitanes et al 2005; Boeddinghaus & Whyte 2008; Hoffman & Islam 2008; Metzger et al 2008; Quereshy et al 2008; Swennen et al 2009) and overall, the Panel was able to make a recommendation:

CBCT is indicated where bone information is required, in orthognathic surgery planning, for obtaining three-dimensional datasets of the craniofacial skeleton

C

4.4.6 Temporomandibular joint

The overwhelming majority of patients with symptoms and signs related to the temporomandibular joint (TMJ) are suffering from myofascial pain/dysfunction or internal disc derangements. Bony abnormality is not seen in the former and only occasionally in the latter. In such cases, radiographs do not add information of relevance to management. Where imaging of the TMJ disc is needed, Magnetic Resonance Imaging (MR) is the method of choice.

Other pathoses encountered in the TMJ include osteoarthritis and rheumatoid arthritis. In both these conditions, there are often bony changes that may be detectable on conventional radiographs and CBCT. When considering the justification for CBCT, however, the clinician should consider whether the information obtained will alter the management of the patient. The identification of bony erosions, remodelling or deformity may be purely documentary and have no impact on treatment strategy.

The available evidence included four diagnostic accuracy studies with valid reference standards (Honda et al 2006; Hintze et al 2007; Honey et al 2007; Marques et al 2010) and a selection of case series/ non-systematic reviews (Zhao et al 2003; Honda et al 2004; Tsiklakis et al 2004; Honda & Bjornland 2006; Sakabe et al 2006; Kijima et al 2007; Krisjane et al 2007; Meng et al 2007; Lewis et al 2008; Huntjens et al 2008; Alexiou et al 2009; Ikeda & Kawamura 2009; Barghan et al 2010; Alkhader et al 2010a; Farronato et al 2010). There was also one systematic review of imaging of TMJ erosions and osteophytes which considered CBCT evidence (Hussain et al 2008) and one recent review of imaging of the TMJ (Petersson 2010).

CBCT images provided similar diagnostic accuracy to MSCT for condylar osseous abnormality (Honda et al 2006) and greater accuracy than panoramic radiography and linear tomography in the detection of condylar cortical erosion (Honey et al 2007). Hintze et al (2007), however, found no differences in diagnostic accuracy for condylar abnormality between CBCT and conventional tomograms. The literature also reveals one comparative study in which CBCT acted as the index test for osseous abnormalities compared with MR (Alkhader et al. 2010b). The latter reported low sensitivity of MR in the detection of osseous change.

While there is good evidence for the accuracy of CBCT for detection of osseous abnormalities of the TMJ, the Panel was not prepared to suggest routine use of CBCT for examination of the TMJ in the absence of evidence about its impact upon treatment decisions. As stated by Petersson (2010), according to the current version of the Research Diagnostic Criteria for Temporomandibular Disorders (RDC/TMD), imaging of the TMJ is not required for a diagnosis. Furthermore, there is no clear

evidence for when TMD patients should be examined with imaging methods. The Panel concluded that CBCT could be considered as an alternative to MSCT, if radiation dose with CBCT is shown to be lower.

Where the existing imaging modality for examination of the TMJ is MSCT, CBCT is indicated as an alternative where radiation dose is shown to be lower

B

4.4.7 References

Abdelkarim A, Green R, Startzell J, Preece J. Craniofacial polyostotic fibrous dysplasia: a case report and review of the literature. *Oral Surg Oral Med Oral Pathol Oral Radiol Endod* 2008; 106: e49-55.

Al-Ekrish AA, Ekram M. A comparative study of the accuracy and reliability of multidetector computed tomography and cone beam computed tomography in the assessment of the dental implant site dimensions. *Dentomaxillofac Radiol* 2011; 40: 67-75.

Alexiou KE, Stamatakis HC, Tsiklakis K. Evaluation of the severity of temporomandibular joint osteoarthritic changes related to age using cone beam computed tomography. *Dentomaxillofac Radiol* 2009; 38: 141-47.

Alkhader M, Kuribayashi A, Ohbayashi N, Nakamura S, Kurabayashi T. Usefulness of cone beam computed tomography in temporomandibular joints with soft tissue pathology. *Dentomaxillofac Radiol*. 2010a; 39: 343-348.

Alkhader M, Ohbayashi N, Tetsumura A, Nakamura S, Okochi K, Momin MA, Kurabayashi T. Diagnostic performance of magnetic resonance imaging of the temporomandibular joint and its correlation with cone beam computed tomography. *Dentomaxillofac Radiol* 2010b; 39: 270-76.

Almog DM, Lamar J, Lamar FR, Lamar F. Cone beam computerized tomography-based dental imaging for implant planning and surgical guidance, Part 1: Single implant in the mandibular molar region. *J Oral Implantol* 2006; 32: 77-81.

Angelopoulos C, Thomas SI, Hechler S, Parisis N, Hlavacek M. Comparison between digital panoramic radiography and cone-beam computed tomography for the identification of the mandibular canal as part of presurgical dental implant assessment. *J Oral Maxillofac Surg* 2008; 66: 2130-2135.

Araki M, Hashimoto K, Kawashima S, Matsumoto K, Akiyama Y. Radiographic features of enostosis determined with limited cone-beam computed tomography in comparison with rotational panoramic radiography. *Oral Radiol* 2006; 22: 27-33.

Araki M, Kameoka S, Mastumoto N, Komiyama K. Usefulness of cone beam computed tomography for odontogenic myxoma. *Dentomaxillofac Radiol* 2007; 36: 423-427.

Aranyarachkul P, Caruso J, Gantes B, Schulz E, Riggs M, Dus I, Yamada JM, Crigger M. (2005) Bone density assessments of dental implant sites: 2. Quantitative cone-beam computerized tomography *Int J Oral Maxillofac Implants* 2005; 20: 416-424.

Arisan V, Karabuda ZC, Özdemir T. Accuracy of two stereolithographic guide systems for computer-aided implant placement: a computed-based clinical comparative study. *J Periodontol* 2010; 81: 43-51.

Balasundaram A, Geist JR, Gordon SC, Klasser GD. Radiographic diagnosis of synovial chondromatosis of the temporomandibular joint: a case report. *J Can Dent Assoc.* 2009; 75 : 711-714.

Barghan S, Merrill R, Tetradis S. Cone beam computed tomography imaging in the evaluation of the temporomandibular joint. *J Calif Dent Assoc.* 2010; 38: 33-39.

Barone A, Covani U, Cornelini R, Gherlone E. Radiographic bone density around immediately loaded oral implants. *Clin Oral Implants Res* 2003; 14: 610-615.

Barragan-Adjemian C, Lausten L, Ang DB, Johnson M, Katz J, Bonewald LF. Bisphosphonate-related osteonecrosis of the jaw: model and diagnosis with cone beam computed tomography. *Cells Tissues Organs* 2009; 189: 284-288.

Blake FAS, Blessmann M, Pohlenz P, Heiland M. A new imaging modality for intraoperative evaluation of sinus floor augmentation. *Int J Oral Maxillofac Surg* 2008; 37: 183-185.

Boeddinghaus R, Whyte A. Current concepts in maxillofacial imaging. *Eur J Radiol* 2008; 66: 396-418.

Bousquet F, Joyard M. Surgical navigation for implant placement using transtomography. *Clin Oral Implants Res* 2008; 19: 724-730.

Bremke, M, Wiegand S, Sesterhenn AM, Eken M, Bien S, Werner JA. Digital volume tomography in the diagnosis of nasal bone fractures. *Rhinology* 2009; 47: 126-131.

Bryant JA, Drage NA, Richmond S. Study of the scan uniformity from an i-CAT cone beam computed tomography dental imaging system. *Dentomaxillofac Radiol.* 2008; 37: 365-74

Caloss R, Atkins K, Stella JP. Three-dimensional imaging for virtual assessment and treatment simulation in orthognathic surgery. *Oral Maxillofac Surg Clin North Am.* 2007; 19: 287-309,

Cevitanes LHS, Bailey LJ, Tucker GR, Styner MA, Mol A, Phillips CL, Proffit WR, Turvey T. Superimposition of 3D cone-beam CT models of orthognathic surgery patients. *Dentomaxillofac Radiol* 2005; 34: 369-375.

Chen L-C, Lundgren T, Hallstrom H, Cherel F. Comparison of different methods of assessing alveolar ridge dimensions prior to dental implant placement. *J Periodontol* 2008; 79: 401-405.

Closmann JJ, Schmidt BL. The use of cone beam computed tomography as an aid in evaluating and treatment planning for mandibular cancer. *J Oral Maxillofac Surg* 2007; 65: 766-771.

Danforth R A, Peck J, Hall P. Cone beam volume tomography: an imaging option for diagnosis of complex mandibular third molar anatomical relationships. *J Calif Dent Assoc* 2003; 31: 847-852.

De Oliveira RCG, Leles CR, Normanha LM, Lindh C, Ribeiro-Rotta RF. Assessments of trabecular bone density at implant sites on CT images. *Oral Surg Oral Med Oral Pathol Oral Radiol Endod* 2008; 105: 231-238.

Drage NA, Sivarajasingam V. The use of cone beam computed tomography in the management of isolated orbital floor fractures. *Br J Oral Maxillofac Surg* 2008; 47: 65-66.

Edwards SP. Computer-assisted craniomaxillofacial surgery. *Oral Maxillofac Surg Clin North Am.* 2010; 22: 117-134.

Eggers G, Welzel T, Mukhamadiev D, Wortche R, Hassfeld S, Muhling J. X-ray-based volumetric imaging of foreign bodies: a comparison of computed tomography and digital volume tomography. *J Oral Maxillofac Surg* 2007; 65: 1880-1885.

Enciso R, Memon A, Mah J. Three-dimensional visualization of the craniofacial patient: volume segmentation, data integration and animation. *Orthod Craniofac Res* 2003; 6 Suppl 1: 66-71; discussion 179-82.

Fan L-F, Pan X-G, Pu Y-P, Lai H-C. Diagnostic value of dental implants in the posterior maxilla using cone beam computed tomography. *Shanghai Kou Qiang Yi Xue* 2008; 17: 548-551.

Farronato G, Garagiola U, Carletti V, Cressoni P, Mercatali L, Farronato D. Change in condylar and mandibular morphology in juvenile idiopathic arthritis: Cone Beam volumetric imaging. *Minerva Stomatol.* 2010; 59: 519-534.

Flygare L, Ohman A. Preoperative imaging procedures for lower wisdom teeth removal. *Clin Oral Investig.* 2008;12: 291-302.

Fortin T, Bosson JL, Coudert JL, Isidori M. Reliability of preoperative planning of an image-guided system for oral implant placement based on 3-dimensional images: an in vivo study. *Int J Oral Maxillofac Implants* 2003; 18: 886-893.

Fortin T, Champleboux G, Bianchi S, Buatois H, Coudert J-L. Precision of transfer of preoperative planning for oral implants based on cone-beam CT-scan images through a robotic drilling machine. *Clin Oral Implants Res* 2002; 13: 651-656.

Friedland B, Donoff B, Dodson TB. The use of 3-dimensional reconstructions to evaluate the anatomic relationship of the mandibular canal and impacted mandibular third molars. *J Oral Maxillofac Surg* 2008; 66: 1678-1685.

Fullmer JM, Scarfe WC, Kushner GM, Alpert B, Farman AG. Cone beam computed tomographic findings in refractory chronic suppurative osteomyelitis of the mandible. *Br J Oral Maxillofac Surg* 2007; 45: 364-371.

Ganz SD. Conventional CT and cone beam CT for improved dental diagnostics and implant planning. *Dent Implantol Update* 2005; 16: 89-95.

Ganz SD. Techniques for the use of CT imaging for the fabrication of surgical guides. *Atlas Oral Maxillofac Surg Clin North Am* 2006; 14: 75-97.

Ganz SD. Computer-aided design/computer-aided manufacturing applications using CT and cone beam CT scanning technology. *Dent Clin North Am* 2008; 52: 777-808.

Ganz SD. Defining new paradigms for assessment of implant receptor sites. The use of CT/CBCT and interactive virtual treatment planning for congenitally missing lateral incisors." *Compendium of Continuing Education in Dentistry* 2010; 29: 256-258.

Garg AK. Dental implant imaging: TeraRecon's Dental 3D Cone Beam Computed Tomography System. *Dent Implantol Update* 2007; 18: 41-45.

Ghaeminia H, Meijer GJ, Soehardi A, Borstlap WA, Mulder J, Bergé SJ. Position of the impacted third molar in relation to the mandibular canal. Diagnostic accuracy of cone beam computed tomography compared with panoramic radiography. *Int J Oral Maxillofac Surg.* 2009; 38: 964-971.

Guerrero ME, Jacobs R, Loubele M, Schutyser F, Suetens P, van Steenberghe D. State-of-the-art on cone beam CT imaging for preoperative planning of implant placement. *Clin Oral Investig* 2006; 10: 1-7.

Guerrero ME, Shahbazian M, Elsiens Bekkering G, Nackaerts O, Jacobs R, Horner K. The diagnostic efficacy of cone beam CT for impacted teeth and associated features: a systematic review. *J Oral Rehabil* 2011; 38: 208-216.

Guttenberg SA. Oral and maxillofacial pathology in three dimensions. *Dent Clin North Am* 2008; 52: 843-873.

Harokopakis-Hajishengallis E, Tiwana P. Odontogenic myxoma in the pediatric patient: a literature review and case report. *Pediatr Dent* 2007; 29: 409-414.

Harris D, Buser D, Dula K, Gröndahl K, Jacobs R, Lekholm U, Nakielny R, van Steenberghe D, van der Stelt P. E.A.O. Guidelines for the use of diagnostic imaging in implant dentistry. *Clin Oral Implants Res* 2002; 13: 566-570.

Hatcher DC, Dial C, Mayorga C. Cone beam CT for pre-surgical assessment of implant sites. *J Calif Dent Assoc* 2003; 31: 825-833.

Heiland M, Schmelzle R, Hebecker A, Schulze D. Intraoperative 3D imaging of the facial skeleton using the SIREMOBIL Iso-C3D. *Dentomaxillofac Radiol* 2004a; 33: 130-132.

Heiland M, Schulze D, Blake F, Schmelzle R. Intraoperative imaging of zygomaticomaxillary complex fractures using a 3D C-arm system. *Int J Oral Maxillofac Surg* 2005; 34: 369-375.

Heiland M, Schulze D, Rother U, Schmelzle R. Postoperative imaging of zygomaticomaxillary complex fractures using digital volume tomography. *J Oral Maxillofac Surg* 2004b; 62: 1387-1391.

Hendriks AW, Maal T, Dieleman F, Van Cann EM, Merks MA. Cone-beam CT in the assessment of mandibular invasion by oral squamous cell carcinoma: results of the preliminary study. *Int J Oral Maxillofac Surg* 2010; 39: 436-439.

Heurich T, Ziegler C, Steveling H, Wortche R, Muhling J, Hassfeld S. Digital volume tomography--an extension to the diagnostic procedures available for application before surgical removal of third molars. *Mund Kiefer Gesichtschir* 2002; 6: 427-432.

Hilgers ML, Scarfe WC, Scheetz JP, Farman AG. Accuracy of linear temporomandibular joint measurements with cone beam computed tomography and digital cephalometric radiography. *Am J Orthod Dentofacial Orthop* 2005; 128: 803-811.

Hintze H, Wiese M, Wenzel A. Cone beam CT and conventional tomography for the detection of morphological temporomandibular joint changes. *Dentomaxillofac Radiol* 2007; 36: 192-197.

Hoffman GR, Islam S. The difficult Le Fort I osteotomy and downfracture: a review with consideration given to an atypical maxillary morphology. *J Plas Reconstr Aesthet Surg* 2008; 61: 1029-1033.

Honda K, Bjornland T. Image-guided puncture technique for the superior temporomandibular joint space: value of cone beam computed tomography (CBCT). *Oral Surg Oral Med Oral Pathol Oral Radiol Endod* 2006; 102: 281-286.

Honda K, Larheim TA, Maruhashi K, Matsumoto K, Iwai K. Osseous abnormalities of the mandibular condyle: diagnostic reliability of cone beam computed tomography compared with helical computed tomography based on an autopsy material. *Dentomaxillofac Radiol* 2006; 35: 152-157.

Honda K, Matsumoto K, Kashima M, Takano Y, Kawashima S, Arai Y. Single air contrast arthrography for temporomandibular joint disorder using limited cone beam computed tomography for dental use. *Dentomaxillofac Radiol* 2004; 33: 271-273.

Honey OB, Scarfe WC, Hilgers MJ, Klueber K, Silveira AM, Haskell BS, Farman AG. Accuracy of cone-beam computed tomography imaging of the temporomandibular joint: comparisons with panoramic radiology and linear tomography. *Am J Orthod Dentofacial Orthop* 2007; 132: 429-438.

Huntjens E, Kiss G, Wouters C, Carels C. Condylar asymmetry in children with juvenile idiopathic arthritis assessed by cone-beam computed tomography. *Eur J Orthod*. 2008; 30: 545-551.

Hussain AM, Packota G, Major PW, Flores-Mir C. Role of different imaging modalities in assessment of temporomandibular joint erosions and osteophytes: a systematic review. *Dentomaxillofac Radiol* 2008; 37: 63-71.

- Ikeda K, Kawaramura A. Assessment of optimal condylar position with limited cone-beam computed tomography. *Am J Orthod Dentofacial Orthop* 2009; 135: 495-501.
- Kamel, SG, Kau CH, Wong ME, Kennedy JW, English JD. The role of Cone beam CT in the evaluation and management of a family with Gardner's syndrome. *J Craniomaxillofac Surg* 2009; 37: 461-468.
- Kijima N, Honda K, Kuroki Y, Sakabe J, Ejima K, Nakajima I. Relationship between patient characteristics, mandibular head morphology and thickness of the roof of the glenoid fossa in symptomatic temporomandibular joints. *Dentomaxillofac Radiol* 2007; 36: 277-281.
- Krisjane Z, Urtane I, Krumina G, Bieza A, Zepa K, Rogovska I. Condylar and mandibular morphological criteria in the 2D and 3D MSCT imaging for patients with Class II division 1 subdivision malocclusion. *Stomatologija* 2007; 9: 67-71.
- Kumar V, Pass B, Guttenberg SA, Ludlow J, Emery RW, Tyndall DA, Padilla RJ. Bisphosphonate-related osteonecrosis of the jaws: a report of three cases demonstrating variability in outcomes and morbidity. *J Am Dent Assoc* 2007; 138: 602-609.
- Lagravère MO, Carey J, Ben-Zvi M, Packota GV, Major PW. Effect of object location on the density measurement and Hounsfield conversion in a NewTom 3G cone beam Computed tomography unit. *Dentomaxillofac Radiol* 2008; 37: 305-308.
- Lagravère MO, Fang Y, Carey J, Toogood RW, Packota GV, Major PW. Density conversion factor determined using a cone-beam computed tomography unit NewTom QE-DVT 9000. *Dentomaxillofac Radiol* 2006; 35: 407-409.
- Lee S, Gantes B, Riggs M, Crigger M. Bone density assessments of dental implant sites: 3. Bone quality evaluation during osteotomy and implant placement. *Int J Oral Maxillofac Implants* 2007; 22: 208-212.
- Lewis EL, Dolwick MF, Abramowicz S, Reeder SL. Contemporary imaging of the temporomandibular joint. *Dent Clin North Am* 2008; 52: 875-890.
- Lloyd TE, Drage NA, Cronin AJ. The role of cone beam computed tomography in the management of unfavourable fractures following sagittal split mandibular osteotomy. *J Orthod* 2011; 38: 48-54.
- Lou L, Lagravère MO, Compton S, Major PW, Flores-Mir, C. Accuracy of measurements and reliability of landmark identification with computed tomography (CT) techniques in the maxillofacial area: a systematic review. *Oral Surg Oral Med Oral Pathol Oral Radiol Endod* 2007; 104: 402-411.
- Loubele M, Guerrero ME, Jacobs R, Suetens P van Steenberghe D. Comparison of jaw dimensional and quality assessments of bone characteristics with cone-beam CT, spiral tomography, and multi-slice spiral CT. *Int J Oral Maxillofac Implants* 2007; 22: 446-454.
- Lübbbers HT, Matthews F, Damerau G, Kruse AL, Obwegeser JA, Grätz KW, Eyrich GK. Anatomy of impacted lower third molars evaluated by computerized tomography: is there an indication for 3-dimensional imaging? *Oral Surg Oral Med Oral Pathol Oral Radiol Endod*. 2010 Oct 15. [Epub ahead of print]
- Mah P, Reeves TE, McDavid WD. Deriving Hounsfield units using grey levels in cone beam computed tomography. *Dentomaxillofac Radiol*. 2010; 39: 323-335.
- Makris N, Stamatakis H, Syriopoulos K, Tsiklakis K, van der Stelt PF. Evaluation of the visibility and the course of the mandibular incisive canal and the lingual foramen using cone-beam computed tomography. *Clin Oral Implants Res*. 2010; 21: 766-771.

Marques AP, Perrella A, Arita ES, Pereira MF, Cavalcanti Mde G. Assessment of simulated mandibular condyle bone lesions by cone beam computed tomography. *Braz Oral Res.* 2010; 24: 467-474

Meng J-H, Zhang W-L, Liu D-G, Zhao Y-P, Ma X-C. Diagnostic evaluation of the temporomandibular joint osteoarthritis using cone beam computed tomography compared with conventional radiographic technology. *Beijing da Xue Xue Bao* 2007; 39: 26-29.

Mengel R, Kruse B, Flores-de-Jacoby L. Digital volume tomography in the diagnosis of peri-implant defects: an in vitro study on native pig mandibles. *J Periodontol* 2006; 77: 1234-1241.

Metzger MC, Hohlweg-Majert B, Schwarz U, Teschner M, Hammer B, Schmelzeisen R. Manufacturing splints for orthognathic surgery using a three-dimensional printer. *Oral Surg Oral Med Oral Pathol Oral Radiol Endod* 2008; 105: e1-7.

Momin MA, Okochi K, Watanabe H, Imaizumi A, Omura K, Amagasa T, Okada N, Ohbayashi N, Kurabayashi T. Diagnostic accuracy of cone-beam CT in the assessment of mandibular invasion of lower gingival carcinoma: comparison with conventional panoramic radiography. *Eur J Radiol* 2009; 72: 75-81.

Moore WS. Cone beam CT: a new tool for esthetic implant planning. *Texas Dent J* 2005; 122: 334-340.

Nackaerts O, Maes F, Yan H, Couto Souza P, Pauwels R, Jacobs R. Analysis of intensity variability in multislice and cone beam computed tomography. *Clin Oral Implants Res.* 2011 Jan 18. doi: 10.1111/j.1600-0501.2010.02076.x. [Epub ahead of print]

Naitoh M, Nakahara K, Suenaga Y, Gotoh K, Kondo S, Arijii E. Comparison between cone-beam and multislice computed tomography depicting mandibular neurovascular canal structures. *Oral Surg Oral Med Oral Pathol Oral Radiol Endod* 2010; 109: e25-31.

Nakagawa Y, Ishii H, Nomura Y, Watanabe NY, Hoshiba D, Kobayashi K, Ishibashi K. Third molar position: reliability of panoramic radiography. *J Oral Maxillofac Surg* 2007; 65, 1303-1308.

Nakagawa Y, Kobayashi K, Ishii H, Mishima A, Ishii H, Asada K, Ishibashi K. Preoperative application of limited cone beam computerized tomography as an assessment tool before minor oral surgery. *Int J Oral Maxillofac Surg* 2002; 31: 322-326.

Nakayama K, Nonoyama M, Takaki Y, Kagawa T, Yuasa K, Izumi K, Ozeki S, Ikebe T. Assessment of the relationship between impacted mandibular third molars and inferior alveolar nerve with dental 3-dimensional computed tomography. *J Oral Maxillofac Surg.* 2009; 67: 2587-2591.

Neugebauer J, Shirani R, Mischkowski R A, Ritter L, Scheer M, Keeve E, Zoller JE. Comparison of cone-beam volumetric imaging and combined plain radiographs for localization of the mandibular canal before removal of impacted lower third molars. *Oral Surg Oral Med Oral Pathol Oral Radiol Endod* 2008; 105: 633-642; discussion 643.

Nickenig H-J, Eitner S. Reliability of implant placement after virtual planning of implant positions using cone beam CT data and surgical (guide) templates. *J Craniomaxillofac Surg* 2007; 35: 207-211.

Nickenig H-J, Eitner S. An alternative method to match planned and achieved positions of implants after virtual planning using cone-beam CT data and surgical guide templates- A method reducing patient radiation exposure (part 1) *Craniomaxillofac Surg* 2010; 38: 436-440.

Nomura Y, Watanabe H, Honda E, Kurabayashi T. Reliability of voxel values from cone-beam computed tomography for dental use in evaluating bone mineral density. *Clin Oral Implants Res.* 2010; 21: 558-562.

Peck JN, Conte GJ. Radiologic techniques using CBCT and 3-D treatment planning for implant placement. *J Calif Dent Assoc* 2008; 36: 287-290.

Petersson A. What you can and cannot see in TMJ imaging - an overview related to the RDC/TMD diagnostic system. *J Oral Rehabil.* 2010; 37: 771-778.

Pires CA, Bissada NF, Becker JJ, Kanawati A, Landers MA. Mandibular Incisive Canal: Cone Beam Computed Tomography. *Clin Implant Dent Relat Res.* 2009 Aug 6. [Epub ahead of print]

Pohlenz P, Blessmann M, Blake F, Gbara A, Schmelzle R, Heiland M. Major mandibular surgical procedures as an indication for intraoperative imaging *J Oral Maxillofac Surg* 2008; 66: 324-329.

Pohlenz P, Blessmann M, Blake F., Heinrich S., Schmelzle R, Heiland M. Clinical indications and perspectives for intraoperative cone-beam computed tomography in oral and maxillofacial surgery. *Oral Surg Oral Med Oral Pathol Oral Radiol Endod* 2007; 103: 412-417.

Popat H, Richmond S, Drage NA. New developments in: three-dimensional planning for orthognathic surgery. *J Orthod.* 2010; 37: 62-71.

Quereshy FA, Savell TA, Palomo JM. Applications of cone beam computed tomography in the practice of oral and maxillofacial surgery. *J Oral Maxillofac Surg* 2008; 66: 791-796.

Razavi T, Palmer RM, Davies J, Wilson R, Palmer PJ. Accuracy of measuring the cortical bone thickness adjacent to dental implants using cone beam computed tomography. *Clin Oral Impl Res* 2010; 21: 718-725.

Rodrigues CD, Estrela C. Traumatic bone cyst suggestive of large apical periodontitis. *J Endod* 2008; 34: 484-489.

Rood JP, Shehab BA. The radiological prediction of inferior alveolar nerve injury during third molar surgery. *Br J Oral Maxillofac Surg* 1990; 28: 20-25.

Rosenberg PA, Frisbie J, Lee J, Lee K, Frommer H, Kottal S, Phelan J, Lin L, Fisch G. Evaluation of pathologists (histopathology) and radiologists (cone beam computed tomography) differentiating radicular cysts from granulomas. *J Endod.* 2010; 36: 423-428.

Rozylo-Kalinowska I, Rozylo TK. Imaging diagnostic approach to tumours of ramus and angle of the mandible. *Annales Universitatis Mariae Curie-Sklodowska - Sectio d – Medicina* 2001; 56: 103-110.

Sakabe R, Sakabe J, Kuroki Y, Nakajima I, Kijima N, Honda K. Evaluation of temporomandibular disorders in children using limited cone-beam computed tomography: a case report. *J Clin Pediatr Dent* 2006; 31: 14-16.

Sarment DP, Sukovic P, Clinthorne N. Accuracy of implant placement with a stereolithographic surgical guide. *Int J Oral Maxillofac Implants* 2003; 18: 571-577.

Sato S, Arai Y, Shinoda K, Ito K. Clinical application of a new cone-beam computerized tomography system to assess multiple two-dimensional images for the preoperative treatment planning of maxillary implants: case reports. *Quintessence Int* 2004; 35: 525-528.

Scarfe WC. Imaging of maxillofacial trauma: evolutions and emerging revolutions. *Oral Surg Oral Med Oral Pathol Oral Radiol Endod* 2005; 100: S75-96.

Scherer P, Mischkowski RA, Seifert H, Ortmann M, Neugebauer J, Scheer M, Zoller J E. Solitary hydatid cyst in the mandible: case report and review of the literature. *J Oral Maxillofac Surg* 2008; 66: 1731-1736.

Schoen R, Fakler O, Metzger MC, Weyer N, Scmelzeisen R. Preliminary functional results of endoscope-assisted transoral treatment of displaced bilateral condylar mandible fractures. *Int J Oral Maxillofac Surg* 2008; 37: 111-116.

Schulze D. Radiographic diagnostics: keratocyst of the left mandible. *Quintessence Int* 2009; 40: 86.

Schulze D, Blessmann M, Pohlenz P, Wagner KW, Heiland M. Diagnostic criteria for the detection of mandibular osteomyelitis using cone-beam computed tomography. *Dentomaxillofac Radiol* 2006; 35: 232-235.

Shintaku WH, Venturin JS, Azevedo B, Noujeim M. Applications of cone-beam computed tomography in fractures of the maxillofacial complex. *Dent Traumatol* 2009; 25: 358-366.

Simon JHS, Enciso R, Malfaz J-M, Roges R, Bailey-Perry M, Patel A. Differential diagnosis of large periapical lesions using cone-beam computed tomography measurements and biopsy. *J Endod* 2006; 32: 883-837.

Sirin Y, Guven K, Horasan S, Sencan S. Diagnostic accuracy of cone beam computed tomography and conventional multislice spiral tomography in sheep mandibular condyle fractures. *Dentomaxillofac Radiol*. 2010; 39: 336-342.

Smith MH, Brooks SL, Eldevik OP, Helman JI. Anterior mandibular lingual salivary gland defect: a report of a case diagnosed with cone-beam computed tomography and magnetic resonance imaging. *Oral Surg Oral Med Oral Pathol Oral Radiol Endod* 2007; 103: e71-8.

Song, YD, Jun SH, Kwon JJ. Correlation between bone quality evaluated by cone-beam computerized tomography and implant primary stability. *Int J Oral Maxillofac Implants* 2009; 24: 59-64.

Stuehmer C, Essig H., Bormann KH, Majdani O, Gellrich NC, Rucker M. Cone beam CT imaging of airgun injuries to the craniomaxillofacial region. *Int J Oral Maxillofac Surg* 2008; 37: 903-906.

Suomalainen A, Vehmas T, Kortnesniemi M, Robinson S, Peltola J. Accuracy of linear measurements using dental cone beam and conventional multislice computed tomography. *Dentomaxillofac Radiol* 2008; 37: 10-17.

Suomalainen A, Ventä I, Mattila M, Turtola L, Vehmas T, Peltola JS. Reliability of CBCT and other radiographic methods in preoperative evaluation of lower third molars. *Oral Surg Oral Med Oral Pathol Oral Radiol Endod*. 2010; 109: 276-284.

Swennen GRJ, Mommaerts MY, Abeloos J, De Clercq C, Lamoral P, Neyt N, Casselman J, Schutyser F. A cone-beam CT based technique to augment the 3D virtual skull model with a detailed dental surface. *Int J Oral Maxillofac Surg* 2009; 38: 48-57.

Tantanapornkul W, Okochi K, Bhakdinaronk A, Ohbayashi N, Kurabayashi T. Correlation of darkening of impacted mandibular third molar root on digital panoramic images with cone beam computed tomography findings. *Dentomaxillofac Radiol*. 2009; 38: 11-16.

Tantanapornkul W, Okouchi K, Fujiwara Y, Yamashiro M, Maruoka Y, Ohbayashi N, Kurabayashi T. A comparative study of cone-beam computed tomography and conventional panoramic radiography in assessing the topographic relationship between the mandibular canal and impacted third molars. *Oral Surg Oral Med Oral Pathol Oral Radiol Endod* 2007; 103: 253-259.

Tsiklakis K, Syriopoulos K, Stamatakis HC. Radiographic examination of the temporomandibular joint using cone beam computed tomography. *Dentomaxillofac Radiol* 2004; 33: 196-201.

Uchida Y, Noguchi N, Goto M, Yamashita Y, Hanihara T, Takamori H, Sato I, Kawai T, Yosue T. Measurement of anterior loop length for the mandibular canal and diameter of the mandibular incisive canal to avoid nerve damage when installing endosseous implants in the interforaminal region: a second attempt introducing cone beam computed tomography. *J Oral Maxillofac Surg*. 2009; 67: 744-750.

van Assche N, van Steenberghe D, Guerrero ME, Hirsch E, Schutyser F, Quirynen M, Jacobs R. Accuracy of implant placement based on pre-surgical planning of three-dimensional cone-beam images: a pilot study. *J Clin Periodontol* 2007; 34: 816-821.

van Assche N, van Steenberghe D, Quirynen M, Jacobs R. Accuracy assessment of computer-assisted flapless implant placement in partial edentulism. *J Clin Periodontol* 2010; 37: 398-403.

van Steenberghe D, Malevez C, van Cleynenbreugel J, Bou Serhal C, Dhoore E, Schutyser F, Suetens P, Jacobs R. Accuracy of drilling guides for transfer from three-dimensional CT-based planning to placement of zygoma implants in human cadavers. *Clin Oral Implants Res* 2003; 14: 131-136.

Yamada T, Ishihama K, Yasuda K, Hasumi-Nakayama Y, Ito K, Yamaoka M, Furusawa K. Inferior Alveolar Nerve Canal and Branches Detected With Dental Cone Beam Computed Tomography in Lower Third Molar Region. *J Oral Maxillofac Surg* 2011 Jan 20. [Epub ahead of print]

Zhao Y-P, Ma X-C, Fu K-Y, Song X-X. Temporomandibular joint disc displacement: diagnosis by arthrography with dental volumetric computerized tomography. *Zhonghua Kou Qiang Yi Xue Za Zhi* 2003; 38: 321-323.

Ziegler CM, Woertche R, Brief J, Hassfeld S. Clinical indications for digital volume tomography in oral and maxillofacial surgery. *Dentomaxillofac Radiol* 2002; 31: 126-130.

Zizelmann C, Gellrich NC, Metzger MC, Schoen R, Schmelzeisen R, Schramm A. Computer-assisted reconstruction of orbital floor based on cone beam tomography. *Br J Oral Maxillofac Surg* 2007; 45: 79-80.

5: CBCT EQUIPMENT FACTORS IN THE REDUCTION OF RADIATION RISK TO PATIENTS

The literature review in section 2.5 showed that the effective dose may vary significantly between different CBCT equipment. In this section, the significance of selection of appropriate exposure settings in limiting doses while maintaining the image quality at acceptable clinical levels (optimisation) is reviewed. Due account was given to any available national recommendations on CBCT optimisation (Haute Autorité de Santé, 2009; Health Protection Agency, 2010; Statens strålevern, 2010).

5.1: X-ray tube voltage and mAs

The kilovoltage (kV_p) of an X-ray tube is the potential difference between anode and cathode during operation. The tube voltage determines the energy of the X-rays. Lower tube voltages give lower energy X-rays and thus increase the dose to the skin of the patient (Horner 1994). Increasing the kV_p may result in a decrease in skin and effective dose (Geijer et al 2009) but an increase in scatter. Higher kV_p , however, reduces the beam hardening effect (Ludlow 2011). More research is needed to explore the optimisation of kV_p in CBCT. The product of the tube current measured in milliamperes (mA) and the exposure time measured in seconds (s) only affects the number of photons emitted by the X-ray tube and not their energy. Increased mAs increases dose, but the beam penetration and image contrast remain the same. The kV_p and mA in dental CBCT equipment is either fixed or can be varied depending on the CBCT unit (Ludlow et al 2006; Lofthag-Hansen et al 2008; Silva et al 2008; Okano et al 2009; Roberts et al 2009). Fixed kV_p and mA preclude optimisation.

The optimisation of radiation dose can be achieved by balancing exposure with image quality needs. Some diagnostic tasks necessitate higher levels of detail to others. The possibility of using “low dose” MSCT for certain tasks in head and neck radiology is established (Loubele et al 2005; Lofthag-Hansen 2010). There is a lack of studies that attempt to optimise these two exposure factors for different CBCT units and clinical protocols. Where “low dose” options are available through reduction in mAs, large reductions in effective dose have been reported (Pauwels et al *in press*); although this study did not assess image quality, it used manufacturers’ low dose protocols. Kwong et al (2008) found that mA and kV_p could be reduced for the equipment studied without a significant loss of image quality. Sur et al 2010 investigated the effect of tube current reduction on image quality for presurgical implant planning in CBCT. They reported that substantial reductions in mA could be made without clinically significant loss of image quality. The work of Lofthag-Hansen et al (2010) also provides ample evidence for the scope for reductions in mAs with acceptable image quality, although they emphasised that exposure parameters should be adjusted to the diagnostic task in question. While these studies must be viewed as specific to the CBCT equipment in question, the weight of evidence in X-ray-based imaging in medicine, along with available national guidelines on optimisation (Haute Autorité de Santé, 2009; Health Protection Agency, 2010; Statens strålevern, 2010), is sufficiently strong to be able to make a recommendation:

KiloVoltage and mAs should be adjustable on CBCT equipment and must be optimised during use according to the clinical purpose of the examination, ideally by setting protocols with the input of a medical physics expert

B

5.2: Field of View and Collimation

CBCT units can be characterised by their Field of View (FOV). The FOV is a cylindrical or spherical volume and determines the shape and size of the reconstructed image. FOVs may vary from a few centimetres in height and diameter to a full head reconstruction. Several CBCT units offer a range of FOV, whilst a fixed FOV is provided by other units. Some CBCT machines offer the option to collimate the beam to the minimum size needed to image the area of interest. The size of the FOV is associated with radiation dose to the patient and staff (Hirsch et al 2008; Okano et al 2009; Roberts et al 2009; Lofthag-Hansen et al 2010; Pauwels et al *in press*).

The study by Pauwels et al (*in press*), conducted as part of the SEDENTEXCT project, demonstrated well the influence of FOV upon effective dose (Fig. 5.1). As can be seen, while each class of FOV shows a wide range of effective dose, there is a clear trend for smaller FOVs to offer lower doses.

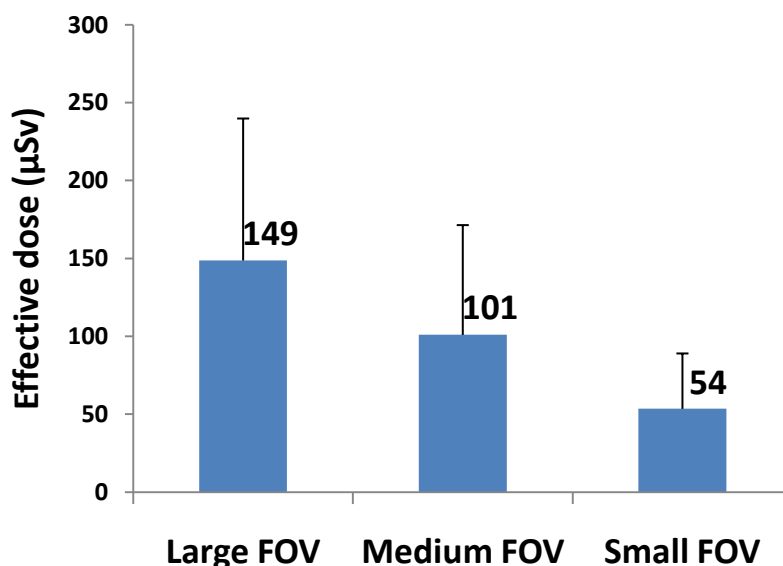


Fig. 5.1: Bar chart showing the effective doses associated with a range of CBCT scanners, classified according to FOV. Adapted from Pauwels et al (*in press*).

Reducing the size of the X-ray beam to the minimum size needed to image the object of interest is, therefore, an obvious means of limiting dose to patients, as well as improving image quality by scatter reduction. Based on the dosimetry evidence and the range of potential clinical applications of CBCT, the Panel judged that equipment with large, fixed FOV was inappropriate for general dental use, where diagnostic tasks are often localised to one, or a few teeth.

Multipurpose dental CBCT equipment should offer a choice of volume sizes and examinations must use the smallest that is compatible with the clinical situation if this provides less radiation dose to the patient

B BP

This recommendation applies to “multipurpose” dental CBCT equipment, used for a variety of clinical applications. In certain situations (e.g. specialised endodontic practice) it is likely that only small volume examinations would be required, and a single [small] field of view option would be appropriate.

5.3: Filtration

Aluminium filtration is an established component of medical X-ray equipment. Some dental CBCT units are equipped with copper filtration. Filtration removes lower energy X-ray photons which results in skin dose reduction but also results in contrast loss (Ludlow et al 2006; Loftag-Hansen et al 2008; Silva et al 2008; Okano et al, 2009; Roberts et al 2009). Kwong et al (2008) found that addition of a copper filter did not affect overall image quality on the CBCT equipment studied. Ludlow (2011) demonstrated that increased copper filtration (in conjunction with a kV change) resulted in a substantial effective dose reduction. Qu et al (2010) cite another manufacturer who has chosen to add copper filtration in a move to optimise dose. Clearly these publications are specific to the equipment studied, and further work on optimising filtration in terms of material and thickness should be performed before a general recommendation can be made.

Research studies on optimisation of filtration for dental CBCT units should be performed

GP

5.4: Digital detector

Dental CBCT units are equipped with digital receptors where the image is captured and formed. Spatial and contrast resolution are important aspects of CBCT detectors which influence image quality.

Two types of digital detectors have been used for dental CBCT units (Hashimoto et al 2003; Ludlow et al 2003; Araki et al 2004; Pasini et al 2007; Loubele et al 2008; Ludlow & Ivanovic 2008; Roberts et al 2009). The first type involves conventional image intensifiers (II). They consist of an input window, input phosphor, photocathode, vacuum and electron optics, output phosphor and output window. The input phosphor converts the X-rays to optical photons which then are converted to electrons within the photocathode. The electrons are accelerated and focused by a series of electrodes and then strike the output phosphor which converts the electrons to light photons which are then captured by various imaging devices. Most modern image intensifiers have cesium iodide for the input phosphor because it is a very efficient material in absorbing X-rays.

The second type, flat panel detectors (FPDs), are composed of an X-ray detection layer and an active matrix array (AMA) of thin film transistors (TFT). The X-ray detector consists of a phosphor layer such as cesium iodide which converts the X-ray photons to light photons. The intensity of the light emitted by the phosphor is a measure of the intensity of the incident X-ray beam. The AMA has a photosensitive element which produces electrons proportional to the intensity of the incident photons. This electrical charge is stored in the matrix until it is read out and it is converted into digital data sent to the image processor. FPDs have greater sensitivity to X-rays than IIs and therefore have the potential to reduce patient dose (Kalender & Kyriakou 2007). They have higher spatial and contrast resolution and fewer artefacts than IIs but, in general, IIs are cheaper than FPDs.

The detector is an important element of the imaging chain and optimisation contributes to dose limitation. The detector is an important element of the imaging chain and optimisation contributes to dose limitation. Balancing the image quality and dose involves the assessment and optimisation of the detector's parameters with relation to dose in the context of image quality and would best be performed in conjunction with a medical physics expert as part of acceptance and commissioning testing (see Section 6.2.2) and in subsequent routine tests.

Dental CBCT units equipped with either flat panel detectors or image intensifiers need to be optimised in terms of dose reduction before use

GP

5.5: Voxel size

The volume element (voxel) represents a three-dimensional (3D) quantity of data and it can be pictured as a 3D pixel. The reconstructed image area or FOV consists of a number of voxels which are isotropic. The voxel size in CBCT systems may vary from less than 0.1 mm to over 0.4 mm (Hashimoto et al 2003; Loubele et al 2008; Liedke et al 2009). Scanning protocols with smaller voxel size are associated with better spatial resolution but with a higher radiation dose to the patient. Voxel size can influence

diagnostic performance, with some tasks which require a high level of detail (see Section 4.3) having been shown to require smaller voxels to optimise diagnostic accuracy (Liedke et al 2009; Kamboroğlu & Kursun 2010; Wenzel et al 2009; Hassan et al 2010; Kamboroglu et al 2010; Melo et al 2010). Qu et al (2010) showed that the “low resolution” option on one CBCT machine substantially reduced patient dose. Clearly, when possible, a low resolution option should be preferred where the nature of the diagnostic task permits. An important consideration in clinical use is that, due to the long scanning times, it is likely that nominal spatial resolutions may not be achieved due to the high probability of motion during the scan.

Multipurpose dental CBCT equipment should offer a choice of voxel sizes and examinations should use the largest voxel size (lowest dose) consistent with acceptable diagnostic accuracy

C

As with section 5.2 (above), this recommendation applies to “multipurpose” dental CBCT equipment. In certain situations (e.g. specialised endodontic practice) it is likely that only high resolution, small volume, examinations would be required.

5.6: Number of projections

The rotation of the X-ray tube and the detector around the patient’s head produces multiple projection images. The total number of acquired projections depends on the rotation time, frame rate (number of projections acquired per second) and on the completeness of the trajectory arc. A high number of projections is associated with increased radiation dose to the patient, higher spatial resolution and greater contrast resolution. Brown et al (2009) have shown that increasing the number of projections does not influence the linear accuracy of CBCT. Reducing the number of projections, while maintaining a clinically acceptable image quality, results in patient dose reduction through a reduction in exposure (mAs).

Some models of CBCT equipment offer the opportunity to perform partial rotations (e.g. 180° instead of the standard 360°), resulting in approximately 50% dose reductions to the patient. Some studies suggest that, for certain clinical applications on specific CBCT equipment, partial rotations can be used while maintaining acceptable diagnostic accuracy and image quality (Lofthag-Hansen et al 2010; Durack et al. 2011). Further research studies should look into the effect of the number of acquired images on the relationship between radiation dose and image quality.

Research studies should be performed to assess further the effect of the number of projections on image quality and radiation dose

GP

5.7: Shielding devices

An alternative way of reducing patient dose is by using shielding devices containing high attenuation materials, such as lead. The thyroid gland is a radiosensitive organ which may be affected by scattered radiation and, occasionally, primary beam in dental CBCT. In Section 2.5 (Fig.2.1) the thyroid gland dose was seen to be an important contributor to effective dose from CBCT, although how much of this is due to internal scatter, which would not be affected by external shielding, is unclear. Tsiklakis et al (2005) have observed a 20% decrease in effective dose by protecting the thyroid gland during CBCT, although this was with a large FOV scanner. In the UK, the guidance (Health Protection Agency 2010) states that the thyroid gland should not normally be in the primary beam during dental CBCT examinations and, therefore, that thyroid shielding should not be necessary. As large FOV scanners are in clinical use, the Panel felt that decisions on the possible value of thyroid shielding should be made locally, ideally with the input of the medical physics expert, depending on the likelihood of the thyroid lying in, or close to, the primary beam. This view is consistent with French guidance (Haute Autorité de Santé, 2009). There is no evidence for the routine use of abdominal shielding (“lead aprons”) during dental CBCT examinations, in line with recommendations for conventional dental radiography.

Shielding devices could be used to reduce doses to the thyroid gland where it lies close to the primary beam. Care is needed in positioning so that repeat exposure is not required. Further research is needed on effectiveness of such devices in dose reduction

GP

5.8: References

Araki K, Maki K, Seki K, Sakamaki K, Harata Y, Sakaino R, Okano T, Seo K. Characteristics of a newly developed dentomaxillofacial X-ray cone beam CT scanner (CB MercuRay): system configuration and physical properties. *Dentomaxillofac Radiol* 2004; 33: 51-59.

Brown AA, Scarfe WC, Scheetz JP, Silveira AM, Farman AG. Linear accuracy of cone beam CT derived 3D images. *Angle Orthod* 2009; 79: 150-157.

Durack C, Patel S, Davies J, Wilson R, Mannocci F. Diagnostic accuracy of small volume cone beam computed tomography and intraoral periapical radiography for the detection of simulated external inflammatory root resorption. *Int. Endod J.* 2011; 44:136-147.

Geijer H, Norrman E, Persliden J. Optimizing the tube potential for lumbar spine radiography with a flat-panel digital detector. *Br J Radiol* 2009; 82: 62-68

Hashimoto K, Arai Y, Iwai K, Araki M, Kawashima S, Terakado M. A comparison of a new limited cone beam computed tomography machine for dental use with a multidetector row helical CT machine. *Oral Surg Oral Med Oral Pathol Oral Radiol Endod* 2003; 95: 371-377.

Hassan B, Metska ME, Ozok AR, van der Stelt P, Wesselink PR.. Comparison of five cone beam computed tomography systems for the detection of vertical root fractures *J Endod* 2010; 36:126-129.

Haute Autorité de Santé. Tomographie Volumique a Faisceau Conique de la Face (Cone Beam Computerized Tomography). Rapport d'évaluation Technologique. Service évaluation des actes professionnels. Saint-Denis La Plaine: Haute Autorité de Santé, 2009. <http://www.has-sante.fr>

Health Protection Agency. Guidance on the Safe Use of Dental Cone Beam CT (Computed Tomography) Equipment. HPA-CRCE-010. Chilton: Health Protection Agency, 2010

Hirsch E, Wolf U, Heinicke F, Silva MA. Dosimetry of the cone beam computed tomography Veraviewepocs 3D compared with the 3D Accuitomo in different fields of view. *Dentomaxillofac Radiol* 2008; 37: 268-273

Horner K. Review article: radiation protection in dental radiology. *Br J Radiol* 1994; 67: 1041-1049.

Kalender WA, Kyriakou Y. Flat-detector computed tomography (FD-CT). *Eur Radiol*. 2007; 17: 2767-2779.

Kamburoğlu K, Kursun S. A comparison of the diagnostic accuracy of CBCT images of different voxel resolutions used to detect simulated small internal resorption cavities. *Int Endod J* 2010; 43: 798-807.

Kamburoğlu K, Murat S, Yüksel SP, Cebeci AR, Paksoy CS. Detection of vertical root fracture using cone-beam computerized tomography: an in vitro assessment. *Oral Surg Oral Med Oral Pathol Oral Radiol Endod*. 2010; 109: e63-69.

Kwong JC, Palomo JM, Landers MA, Figueroa A, Hans MG. Image quality produced by different cone-beam computed tomography settings. *Am J Orthod Dentofacial Orthop*. 2008; 133: 317-327.

Liedke GS, da Silveira HE, da Silveira HL, Dutra V, de Figueiredo JA. 2009. Influence of voxel size in the diagnostic ability of cone beam tomography to evaluate simulated external root resorption. *J Endod* 2009; 35: 233-235.

Lofthag-Hansen. Cone Beam Computed Tomography. Radiation Dose and Image Quality assessments. PhD thesis: Sahlgrenska Academy, University of Gothenburg, 2010.

Lofthag-Hansen S, Thilander-Klang A, Ekestubbe A, Helmrot E, Gröndahl K. Calculating effective dose on a cone beam computed tomography device: 3D Accuitomo and 3D Accuitomo FPD. *Dentomaxillofac Radiol* 2008; 37: 72-79

Lofthag-Hansen S, Thilander-Klang A, Gröndahl K. Evaluation of subjective image quality in relation to diagnostic task for cone beam computed tomography with different fields of view. *Eur J Radiol*. 2010 Oct 19. [Epub ahead of print]

Loubele M, Bogaerts R, Van Dijck E, Pauwels R, Vanheusden S, Suetens P, Marchal G, Sanderink G, Jacobs R. Comparison between effective radiation dose of CBCT and MSCT scanners for dentomaxillofacial applications. *Eur J Radiol*. 2009; 71: 461-468.

Loubele M, Jacobs R, Maes F, Schutyser F, Debaveye D, Bogaerts R, Coudyzer W, Vandermeulen D, van Cleynenbreugel J, Marchal G, Suetens P. Radiation dose vs. image quality for low-dose CT protocols of the head for maxillofacial surgery and oral implant planning. *Radiat Prot Dosimetry*. 2005; 117: 211-216.

- Ludlow JB. A manufacturer's role in reducing the dose of cone beam computed tomography examinations: effect of beam filtration. *Dentomaxillofac Radiol.* 2011; 40: 115-122.
- Ludlow JB, Davies-Ludlow LE, Brooks SL. Dosimetry of two extraoral direct digital imaging devices: NewTom cone beam CT and Orthophos Plus DS panoramic unit. *Dentomaxillofac Radiol* 2003; 32: 229-234.
- Ludlow JB, Davies-Ludlow LE, Brooks SL, Howerton WB. Dosimetry of 3 CBCT devices for oral and maxillofacial radiology: CB Mercuray, NewTom 3G and i-CAT. *Dentomaxillofac Radiol* 2006; 35: 219-226
- Ludlow JB, Ivanovic M. Comparative dosimetry of dental CBCT devices and 64-slice CT for oral and maxillofacial radiology. *Oral Surg Oral Med Oral Pathol Oral Radiol Endod* 2008; 106:106-114.
- Melo SL, Bortoluzzi EA, Abreu M Jr, Corrêa LR, Corrêa M. Diagnostic ability of a cone-beam computed tomography scan to assess longitudinal root fractures in prosthetically treated teeth. *J Endod.* 2010; 36:1879-1882.
- Okano T, Harata Y, Sugihara Y, Sakaino R, Tsuchida R, Iwai K, Seki K, Araki K. Absorbed and effective doses from cone beam volumetric imaging for implant planning. *Dentomaxillofac Radiol* 2009; 38: 79-85.
- Pasini A, Casali F, Bianconi D, Rossi A and Bontempi M. A new cone-beam computed tomography system for dental applications with innovative 3D software. *Int J CARS* 2007;1: 265-273.
- Pauwels R, Beinsberger J, Collaert B, Theodorakou C, Rogers J, Walker A, Cockmartin L, Bosmans H, Jacobs R, Bogaerts R, Horner K The SEDENTEXCT Project Consortium. Effective dose range for dental cone beam computed tomography scanners. *Eur J Radiol.* 2010 Dec 31. [Epub ahead of print]
- Qu XM, Li G, Ludlow JB, Zhang ZY, Ma XC. Effective radiation dose of ProMax 3D cone-beam computerized tomography scanner with different dental protocols. *Oral Surg Oral Med Oral Pathol Oral Radiol Endod.* 2010; 110: 770-6.
- Roberts JA, Drage NA, Davies J, Thomas DW. Effective dose from cone beam CT examinations in dentistry. *Br J Radiol* 2009; 82: 35-40.
- Scarfe WC, Levin MD, Gane D, Farman AG. Use of cone beam computed tomography in endodontics. *Int J Dent* 2009; 2009:634567. Epub 2010 Mar 31.
- Silva MA, Wolf U, Heinicke F, Bumann A, Visser H, Hirsch E. Cone-beam computed tomography for routine orthodontic treatment planning: a radiation dose evaluation. *Am J Orthod Dentofacial Orthop* 2008; 133: 640.e1-5.
- Sur J, Seki K, Koizumi H, Nakajima K, Okano T. Effects of tube current on cone-beam computerized tomography image quality for presurgical implant planning in vitro. *Oral Surg Oral Med Oral Pathol Oral Radiol Endod.* 2010; 110: e29-33
- Statens strålevern. Stråleverninfo 8:2010. Krav for bruk av Cone Beam CT ved odontologiske virksomheter. Østerås: Statens strålevern, 2010.
- Tsiklakis K, Donta C, Gavala S, Karayianni K, Kamenopoulou V, Hourdakakis CJ. Dose reduction in maxillofacial imaging using low dose Cone Beam CT. *Eur J Radiol* 2005; 56: 413-417.
- Wenzel A, Haiter-Neto F, Frydenberg M, Kirkevang LL. Variable-resolution cone-beam computerized tomography with enhancement filtration compared with intraoral photostimulable phosphor radiography in detection of transverse root fractures in an in vitro model. *Oral Surg Oral Med Oral Pathol Oral Radiol Endod.* 2009; 108: 939-945.

6: QUALITY STANDARDS AND QUALITY ASSURANCE

6.1 Quality assurance programme

The purpose of Quality Assurance (QA) in dental radiology is to ensure consistently adequate diagnostic information, while radiation doses are controlled to be as low as reasonably achievable.

A well-designed QA programme should be comprehensive but inexpensive to operate and maintain for the dentist and staff. It should cover all aspects of the imaging process, including objective measures of the imaging equipment performance, patient dose audit and an assessment of clinical image quality. Such a programme will include the following:

- Performance of the X-ray tube and generator
- Quantitative assessment of image quality
- Display screen performance
- Patient dose assessment
- Clinical image quality assessment
- Clinical audit

Those aspects of the programme that deal primarily with equipment performance and patient dose are commonly referred to as quality control (QC). A QC programme will include surveys and checks that are performed according to a regular timetable. A written record of this programme should be maintained by staff to ensure adherence to the programme and to raise its importance among staff. A specific person should be named as leader for the QC programme.

In addition, assessment of the clinical images and other clinical audit should be undertaken on a regular basis to confirm that the equipment is being used correctly to produce clinically useful images.

In preparing this Section, due account was given to relevant sections of published national guidelines on dental CBCT in Belgium (Advies van de Hoge Gezondheidsraad, 2011), Denmark (Sundhedsstyrelsen, 2009), France (Haute Autorité de Santé, 2009), Germany (Leitlinie der DGZMK, 2009), Norway (Statens strålevern, 2010) and the United Kingdom (Health Protection Agency, 2010a and 201b).

6.2: Equipment performance

A programme of testing X-ray equipment performance is a requirement of the European Union Medical Exposures Directive (Council Directive 97/43/Euratom, 1997) as part of the optimisation process to ensure patient dose is as low as reasonably achievable whilst achieving clinically adequate image quality. The rationale for maintenance and testing of a dental CBCT system is similar to that of other dental systems (European Commission 2004) and for X-ray equipment in general (IPEM91

2005) and will consist of a critical examination and acceptance and commissioning testing when first installed, followed by routine testing throughout the life of the equipment. As both patient and operator dose are potentially higher than for traditional dental X-ray equipment, greater care is required for dental CBCT in all aspects of an equipment QC programme.

Ideally, any practice undertaking medical exposure should have access to the advice of a qualified expert for advice on radiation protection and a medical physics expert for advice on patient dose optimisation and equipment testing. Their help and advice should be sought in devising a suitable equipment testing regime. In some countries, there is no requirement for the appointment of a medical physics expert to dental practices using CBCT, for example in Denmark (Sundhedsstyrelsen, 2009) and Germany. The Panel suggest, however, that the relative radiation dose implications of some CBCT systems are such that it would be advisable to have a formal arrangement to obtain MPE advice.

Preliminary guidance on testing dental CBCT is now available, both within these Guidelines (Appendix 4) and from the UK (HPA 2010a) outlining the basic tests to be undertaken, both when the equipment is first installed and then on a regular basis throughout the life of the equipment. The QC protocol developed by the SEDENTEXCT project is given in Appendix 4 to these guidelines.

Suggested performance guidelines are also provided so that users can assess whether their unit is operating consistently and in line with expectation for these types of units. However, it should be remembered that this technology is still relatively new and is developing rapidly. The tests and performance guidelines should be kept under critical review and may well be subject to change as experience is gained in testing such units.

Some of the tests require specially devised phantoms. Such phantoms are commercially available, including that developed during the SEDENTEXCT project (Leeds Test Objects Ltd., Boroughbridge, UK). Some manufacturers of dental CBCT systems also provide a quality assurance phantom with their system, which should come with recommendations on the tests that should be performed, the best way to perform them, how often they should be performed and how the results should be interpreted. Some of these quality assurance phantoms, including the SEDENTEXCT phantom, are also provided with software which automatically performs analysis of the acquired image.

Published equipment performance criteria should be regularly reviewed and revised as greater experience is acquired in testing dental CBCT units

GP

6.2.1 Critical examination

A critical examination of the installation is required to ensure that all safety features are correctly installed and functioning and that adequate protection is provided to the

operator and anyone else who may be in the area. This will usually be more onerous than for other dental equipment due to the higher protection requirements, both in terms of structural protection and warning systems. As expanded in Section 7.2, the structural protection required for a dental CBCT system is greater than for conventional dental imaging equipment and greater care must be taken in the room design to ensure adequate protection for both operator and others in areas adjacent to the unit. In particular, it cannot be assumed that CBCT systems can be installed in rooms designed for intraoral and panoramic dental systems without further work being undertaken.

6.2.2 Acceptance and commissioning tests

The main aim of the acceptance and commissioning tests is to ensure the imaging system is as specified and working at an acceptable performance level for the specific clinical indications in the local practice. These tests should usually be performed by a medical physics expert.

The essential content of these tests includes:

- testing of equipment performance parameters
- acquiring base line values for future routine tests
- verification of how the systems are pre-programmed for use in practice

All acceptance and commissioning testing protocols include tests of the X-ray tube output, voltage consistency and accuracy, filtration, exposure time and radiation field. These can be tested in the same way as for other modalities, like general radiology digital detector systems or MSCT scanners. A dosimeter with wave form display may be helpful to confirm correct operation of the X-ray tube. Testing of the correct operation of any automatic exposure control device, if fitted, is also essential.

Classical tests of digital detectors (linearity, homogeneity, spatial resolution, low contrast resolution, (dark) noise, etc.) can be run if unprocessed raw data of the projective images are available. Reconstruction software can be tested indirectly via an assessment of image quality, using test objects with specific inserts. At present, there are no standardized reconstruction software tools available that would allow comparative studies among modalities. With ever more sophisticated acquisition schemes (like variable angles, off-axis radiation, tube output modulation, different FOVs, etc.) it is very unlikely that the reconstruction software will be standardized in the future.

6.2.3 Routine tests

Both medical physics experts and local personnel have a role in routine tests. A typical frequency for medical physics tests is annually (Health Protection Agency 2010a, 2010b; Statens strålevern, 2010). Local personnel should run a series of routine consistency tests more frequently in line with current national guidance, usually monthly (Qualitätssicherungs-Richtlinie, 2004; Health Protection Agency 2010a, 2010b; Statens strålevern, 2010). When introducing a new modality, its operation should be monitored more frequently, until the system is working reliably at its optimal point in terms of dose and image quality. Optimisation studies may be advisable at this stage.

Routine testing may be helped with automatic procedures built into the system. These can include the evaluation of test objects against performance levels set by the company or by national or international protocols, the review of retakes (automatically stored into the system) and system self checks. Full documentation should be provided by the installers on these (automated) procedures. Exportable reports are preferable.

A simple but very sensitive test for constancy checks in digital imaging is a regular acquisition of a homogeneous block of material. Local artefacts in the digital detector induce (usually circular) artefacts in the reconstructed slices. Tube- or detector-related instabilities would produce variations in signal intensities.

It is important that the performance of the display equipment and environment is also monitored, as well as the X-ray equipment and detectors, as these can lead to significant degradation of the image being used by the clinician.

Testing of dental CBCT should include a critical examination and detailed acceptance and commissioning tests when equipment is new and routine tests throughout the life of the equipment. Testing should follow published recommendations and a Medical Physics Expert should be involved.

ED BP

6.3 Patient dose

An objective of the QA programme is to ensure doses are kept as low as reasonably achievable. It is, therefore, necessary to ensure that patient doses are monitored on a regular basis and compared to agreed standards. Standard dose levels are normally referred to as Diagnostic Reference Levels (DRLs) as described in the European Guidelines No 136 (European Commission 2004).

6.3.1 Dose quantities

Dose quantities that are to be used for the regular assessment of patient dose must be relatively easy to measure in a clinical situation. Although effective dose is usually considered to be the best overall descriptor of patient dose, it can not be readily measured and a simpler quantity is required for routine dose audit. Entrance surface dose (ESD) and dose area product (DAP) are quantities that are routinely used in conventional radiology (European Commission 1999). In the field of CT, the computed tomography dose index (CTDI), and dose length product, DLP, are routinely used. Ideally, the dose quantity used should give a good correlation to the effective dose and hence overall patient risk.

In the UK, the Health Protection Agency has proposed the use of DAP (HPA 2010). This is promising as it provides one reading per exposure that gives an indication of

both the dose level in the beam and the area irradiated. Some CBCT units already provide this information after each exposure. If this became universal, as CT scanners now all provide an indication of DLP, it would greatly facilitate patient dose audit. The accuracy of such readouts should be checked by the medical physics expert during routine testing.

Alternative proposals have been explored by the SEDENTEXCT team and dose indices based on point measurement within PMMA phantoms have been proposed (see patient dose section in Appendix 4). Further work is, however, required to establish whether such indices are appropriate for the setting of DRLs.

Manufacturers of dental CBCT equipment should provide a read-out of Dose-Area-Product (DAP) after each exposure

D

6.3.2 Establishing Diagnostic Reference Levels

The UK's Health Protection Agency have carried out a preliminary audit of DAP across 41 dental CBCT units and have proposed an achievable dose of 250 mGy cm² for CBCT imaging appropriate for the placement of an upper first molar implant in a standard adult patient. It should be noted that large FOV units in the sample exceed this and the dose audit data had been normalised to an area corresponding to a 4cm x 4cm field of view at the isocentre of the equipment. It is for this reason that they have referred to this dose level as an "achievable dose" rather than a DRL. It is indicative of the dose that should be achieved if using a CBCT unit suitable for this clinical use. Some dental implant systems require "full arch" imaging as part of the needs for manufacture of imaging guides/stents. Authorities or clinicians performing dose audit should specify that this requirement should be suspended for the dose measurement and the smallest field of view compatible with single implant site assessment used.

They also propose setting a DRL for a child view based on the clinical protocol used to image a single impacted maxillary canine in a 12 year old male. As yet, however, insufficient audit data is available to set this level.

Further work involving large scale audits is needed to establish robust DRLs for a range of dental CBCT applications that can aid in the patient dose optimisation process.

Until further audit data is published, the panel recommend the adoption of an achievable Dose Area Product of 250 mGy cm² for CBCT imaging for the placement of an upper first molar implant in a standard adult patient

D

6.3.3 Using DRLs

Dentists should be aware of their average doses for the different types of examinations they undertake with their CBCT equipment and how these compare with the European and any national DRLs, once established.

If a DAP readout is provided on the equipment, the dentist should undertake audit of DAP readings for standard size patients, ideally with the help of a medical physics expert. If DAP is not provided it is expected that the dentist will need to seek help from the medical physics expert to establish typical patient doses. These assessments should be carried out on a regular basis, at least every three years or as required by national legislation.

These measurements can be seen to be a part of any QA programme adopted by the dental practice. Dose results that exceed established DRLs, or which significantly differ from previous audits, should be investigated with the help of a medical physics expert. Any resulting recommendations should be implemented.

It should be noted that CBCT units with fixed large FOV are likely to exceed the achievable dose stated above for the placement of an upper first molar implant in a standard adult patient. Consideration must be given as to whether the use of such a unit for this view can be considered to be justified.

A cone beam dental system usually comes with pre-programmed settings for different types of patients (e.g. children versus adults) or clinical indications. In the absence of any patient specific tube output modulation, the pre-programmed protocols can be verified by means of dose measurements in air, at the level of the detector, or using a DAP meter. In the ideal case, the dose measurements are performed for all standard imaging protocols for which a DRL has been defined. When tube output modulation is used, dedicated phantoms may be required or clinical dose audit based on a group of standard patients.

It is good practice to investigate whether the doses have been selected based upon relevant criteria. In particular, it should be verified that doses for children are significantly lower than those for adults and that separate programs are available for local pathologies as well as imaging the complete upper or lower jaw. Other settings to be tested include the correct pre-programming of lower kV, the use of tube output modulation, high versus low resolution scanning etc.

Systematic patient dose surveys are straightforward if DICOM header tags are completely filled in and if software is available to obtain the dose related information automatically. The intrinsic dose information has first to be checked against measured data, has then to be expressed or recalculated into survey related quantities and then be collected over a period of time. The medical physics expert should ensure that the practitioner is aware if DRLs are exceeded.

6.4: Clinical Image Quality Assessment

The consistent production of adequate diagnostic information from radiological examinations is central to optimization (EC Directive 97/43 Euratom). There is,

however, ample research evidence showing that radiographic image quality is often less than ideal in primary dental care (reviewed in European Commission 2004). The higher radiation doses of CBCT compared with conventional dental radiography mean that standards must be rigorously maintained.

In addition to the assessment of image quality by quantitative methods, as described above in the image quality section, it is important that the quality of clinical images is assessed. This can be approached in three ways:

1. Comparison with standard reference images from high quality CBCT examinations.
2. Reject analysis, in which the rate of unsuccessful CBCT examinations is recorded and the reasons for rejection analysed.
3. Systematic audit of CBCT examinations against established clinical image quality criteria.

*Assessment of the clinical quality of images should be
a part of a quality assurance programme for CBCT
GP*

6.4.1 Comparison with standard reference images

This is a long-established method of continuous monitoring of clinical image quality and helps to guard against a gradual drift away from optimal quality which may occur in practice over time. A CBCT scan dataset of excellent quality is used as a reference, against which everyday clinical scans can be assessed. Because of readily apparent differences in the appearance of CBCT datasets produced by different CBCT machines, reference scans need to be prepared which are specific to each machine. This might best be done by the manufacturer and supplied with the equipment. There is, however, a potential conflict between this approach for assessing image quality and optimization efforts which may employ reduced exposures that are sufficient to achieve *adequate* image quality for the clinical task. Thus, adequate quality images may fall short of the quality of an excellent reference image. As such, standard reference CBCT scan datasets should be available which are specific not only to the machine, but also to the diagnostic task.

6.4.2 Reject analysis

A simple and valuable tool in clinical image QC is reject analysis. Over a specified time period, a record is kept of radiological examinations that are rejected and that require repeats to be performed, with the date and the reason for the rejection (e.g. area of interest not imaged, image blurred etc.) and the cause if known (e.g. incorrect positioning, patient movement etc.). This allows the calculation of the proportion of examinations which are rejected over a specified period and the identification of the most frequent causes of rejection. Reject analysis can be carried out prospectively (as images are performed) and/or retrospectively. When performed retrospectively, this procedure is a form of Clinical Audit, which requires assessment against a clearly defined set of Quality Standards. Table 6.1 provides a means of comparing CBCT examinations against a standard.

Table 6.1: Clinical Quality Standards for CBCT images

<p>A. Adequate patient preparation, positioning and instruction</p> <ul style="list-style-type: none"> • No removable metallic foreign bodies which might produce scan artefacts (e.g. earrings, spectacles, dentures) • No motion artefacts • No evidence of incorrect positioning of imaging guides/stents (e.g. air gap due to incorrect seating of the stent) • Where fixed, metallic, restorations are in the teeth, no artefacts overlying the area of primary interest¹.
<p>B. Correct anatomical coverage</p> <ul style="list-style-type: none"> • Evidence that the smallest Field of View available on the equipment has been used, consistent with the clinical application. • The primary area of interest² at or near the centre of the Field of View. • All of the area of interest included in the scan volume.
<p>C. Adequate exposure factors used</p> <ul style="list-style-type: none"> • Absence of significant image noise, low density and contrast
<p>¹<i>It is recognised that it may not always be possible to exclude restoration-related artefacts, but there should be evidence that every effort has been made to limit their impact (e.g. by careful orientation of the occlusal plane during positioning).</i></p> <p>²<i>e.g. single tooth or single implant site. It is recognised that where multiple implant sites or larger structures are being imaged, not all can be central in the scan volume.</i></p>

The European Guidelines on Radiation Protection in Dental Radiology (2004) recommended that, as part of a Clinical Audit of film rejects, conventional radiographs be assessed into one of three categories: “Excellent” (no faults), “Acceptable” (some faults but not affecting image interpretation) and “Unacceptable” (faults leading to the radiograph being unacceptable for interpretation). Furthermore, a minimum target was set that no more than 10% of radiographs should be of unacceptable quality. As stated above, the higher radiation doses often seen with CBCT compared with conventional dental radiography imply that a more rigorous quality standard may be appropriate. No published studies on reject rates for dental CBCT examinations were identified by literature review. The only available recommendation identified in this area was that published in the UK (Health Protection Agency, 2010), which recommended a performance standard (minimum target) of not greater than 5% of CBCT examinations classified as “Unacceptable”. The SEDENTEXCT Guideline Development Panel concluded that this was a pragmatic recommendation in the absence of published evidence of reject rates with CBCT. The achievement of this target of 5% should not be seen as an excuse to relax efforts to improve quality or cease image quality assessments. Clinical Audit should be a cycle of quality improvement, relying on repeated assessments against quality standards and implementation of change. Table 6.2 considers corrective actions that might be taken as part of a Clinical Audit cycle.

Establishments carrying out CBCT examinations should perform reject analysis, either prospectively or as part of retrospective clinical audit, at intervals no greater than once every six months

GP

As a minimum target, no greater than 5% of CBCT examinations should be classified as “unacceptable”. The aim should be to reduce the proportion of unacceptable examinations by 50% in each successive audit cycle

GP

6.4.3 Audit against established clinical image quality criteria

Visual grading of anatomical features on medical images is a standard method of assessing image quality. Criteria have been established for several types of medical imaging, including adult and paediatric radiography and CT (Report EUR 16260, 1996; Report EUR 16261, 1996; Report EUR 16262, 1999). The aim of such criteria is to characterize a level of acceptability of medical images which can address any clinical indication.

The image quality criteria established for CT (Report EUR 16262, 1999) have little relevance to dental CBCT and there are no comparable established criteria for image quality assessment for the wide range of uses of dental CBCT. Loftag-Hansen et al (2010) described sets of statements used by observers in their study to assess the adequacy of clinical image quality for two uses in upper and lower jaws: implant planning and periapical diagnosis. In their study, these statements proved to be a useful tool in optimisation of radiation doses and can be seen as a good example of how image quality criteria for CBCT might be used. There is, however, a need for further research to develop a comprehensive set of image quality criteria for CBCT that reflect the range of equipment types and their varying clinical capabilities. Ideally, this should be done at a European level rather than various national criteria, as this would assist equipment manufacturers in their work. Until such time as this has been accomplished, clinical image quality assessment must rely either upon the simpler methods described in 6.4.1 and 6.4.2, or by the local development of image quality criteria.

Image quality criteria should be developed for dental CBCT, ideally at the European level

GP

Table 6.2: An aid to reject analysis of CBCT examinations

Fault category	Observed fault	Cause	Corrective action
Patient preparation	Streak artefacts over area of interest.	Failure to take out removable metallic objects before scanning (e.g. dentures, earrings and other piercings).	<ul style="list-style-type: none"> Careful pre-scanning procedures to observe and ask patients about removable objects.
	Imaging stent not in the correct anatomical position. May be recognised by an air gap under the stent on scans.	Inadequate care in placing the stent or an ill-fitting stent.	<ul style="list-style-type: none"> Greater care in positioning the stent and checking position prior to imaging.
	Blurring of image.	<ul style="list-style-type: none"> Patient movement. Failure to instruct patient, or to judge suitability of patient for scanning. 	<ul style="list-style-type: none"> Procedures to instruct the patient to stay still. Consider past experience with patient's cooperation and ensure careful observation of patient during positioning. Use all available immobilisation aids (head restraints, chin rest, etc).
Patient positioning	All, or part of, the area of interest excluded from the scan volume.	<ul style="list-style-type: none"> Failure to position the scan volume over the area of interest during preparation. Patient movement between initial positioning and exposure. Field of View too small for the diagnostic task. 	<ul style="list-style-type: none"> Use all available positioning aids (e.g. light beams). Omission of scout views should only be considered under highly selected situations and where alternative positioning aids are fully employed. Protocol to instruct the patient to stay still. Use all available immobilisation aids (head restraints, chin rest, etc.).
	Streak artefacts over area of interest.	The source of streak artefacts is in the same plane as the area of interest.	<ul style="list-style-type: none"> Consider tipping the head to reduce the impact of artefacts from non-removable objects (dental restorations).
Exposure	Increased "graininess" and reduced sharpness of the image.	Exposure factors too low (kV, mA, reduced number of basis images).	<ul style="list-style-type: none"> Establish exposure protocols to match patient size and the clinical purpose of examination.
Post acquisition manipulation error	Poor contrast and brightness.	Using the image data as acquired, with failure to optimise the contrast and brightness.	<ul style="list-style-type: none"> Operator training Appropriate use of density and contrast controls.
	"Pseudoforamina" in volume-rendered images.	Incorrect thresholding.	<ul style="list-style-type: none"> Operator training Appropriate use of windowing controls.
	Incomplete diagnostic information or exclusion of area of interest on reconstructed images.	Inappropriate positioning or thickness of reformatted image slices.	<ul style="list-style-type: none"> Operator training in multiplanar reformatting.

6.5: References

Advies van de Hoge Gezondheidsraad nr. 8705. Dentale Cone Beam Computed Tomography. Brussel: Hoge Gezondheidsraad, 2011. www.hgr-css.be

Council Directive 97/43/Euratom of 30 June 1997 on health protection of individuals against the dangers of ionizing radiation in relation to medical exposure Official Journal of the European Communities No L 180/11 1997

European Commission 2004. Radiation Protection 136. European Guidelines on Radiation Protection in Dental Radiology. Luxembourg: Office for Official Publications of the European Communities,. Available from: http://ec.europa.eu/energy/nuclear/radioprotection/publication/doc/136_en.pdf

IPEM 2005 Recommended standards for the routine performance testing of diagnostic X-ray imaging systems IPEM report 91

Haute Autorité de Santé. Tomographie Volumique a Faisceau Conique de la Face (Cone Beam Computerized Tomography). Rapport d'évaluation Technologique. Service évaluation des actes professionnels. Saint-Denis La Plaine: Haute Autorité de Santé, 2009. <http://www.has-sante.fr>

Health Protection Agency Recommendations for the design of X-ray facilities and quality assurance of dental Cone Beam CT (Computed tomography) systems HPA-RPD-065 JR Holroyd and A Walker. Chilton: Health Protection Agency, 2010a.

Health Protection Agency. Guidance on the Safe Use of Dental Cone Beam CT (Computed Tomography) Equipment. HPA-CRCE-010. Chilton: Health Protection Agency, 2010b.

Lofthag-Hansen S, Thilander-Klang A, Gröndahl K. Evaluation of subjective image quality in relation to diagnostic task for cone beam computed tomography with different fields of view. Eur J Radiol. 2010 Oct 19. [Epub ahead of print]

Qualitätssicherungs-Richtlinie – QS-RL. Richtlinie zur Durchführung der Qualitätssicherung bei Röntgeneinrichtungen zur Untersuchung oder Behandlung von Menschen nach den §§ 16 und 17 der Röntgenverordnung. Gemeinsames Ministerialblatt 37-38, 2004, S. 731-777.

Report EUR 16260. Carmichael JHE, Maccia C, Moores BM, Oestmann JW, Schibilla H, Teunen D, van Tiggelen R, Wall B. (Eds.). Quality Criteria for Diagnostic Radiographic Images. Luxembourg: Office for Official Publications of the European Communities, 1996.

Report EUR 16261. Kohn MM, Moores BM, Schibilla H, Schneider K, St. Stender H, Stieve FE, Teunen D, Wall B. (Eds.). European Guidelines on Quality Criteria for Diagnostic Radiographic Images in Paediatrics. Luxembourg: Office for Official Publications of the European Communities, 1996.

Report EUR 16262. Menzel H-G, Schibilla H, Teunen D, (Eds.). European Guidelines on Quality Criteria for Computed Tomography. Luxembourg: Office for Official Publications of the European Communities, 1999.

Statens strålevern. Stråleverninfo 8:2010. Krav for bruk av Cone Beam CT ved odontologiske virksomheter. Østerås: Statens strålevern, 2010.

Sundhedsstyrelsen. Statens Institut for Strålebeskyttelse. Krav til 3D dental. Herlev: Statens Institut for Strålebeskyttelse, 2009.

European Commission 1999. Radiation Protection 109. Guidance on Diagnostic Reference Levels (DRLs) for Medical Exposures. Luxembourg: Office for Official Publications of the European Communities,.

7: STAFF PROTECTION

The general comments on protection of staff made in the European Guidelines No 136 (European Commission 2004) are equally applicable to dental CBCT. However, as dose levels and beam energies are generally higher compared to conventional dental radiology, extra practical protection measures are required for dental CBCT. It is essential that an appropriate qualified expert is consulted both prior to installation and on an on-going basis.

It is essential that a Qualified Expert is consulted over the installation and use of CBCT to ensure that staff dose is as low as reasonably achievable and that all relevant national requirements are met

ED D

7.1 Classification of areas

The European Guidelines No 136 (European Commission 2004) recommended that the use of distance to reduce dose was normally the only measure required for conventional dental radiography. Data on dose rates around CBCT units are not available in the literature, but doses measured in the field and information available from manufacturers indicate that the maximum dose at 1 metre due to scattered radiation varies between 2 to 47 μSv per scan, compared with intraoral and panoramic radiography scatter doses of less than 1 μSv per exposure.

In addition, tube voltage can be as high as 120kVp, leading to scattered radiation being significantly more penetrating. This is much higher than conventional dental radiography and the increased penetration through protective shielding must also be borne in mind.

Consequently, it is recommended that CBCT equipment be installed in a purpose-built enclosure providing adequate protection to adjacent areas and the operator and that the whole of this enclosure be designated a controlled area.

CBCT equipment should be installed in a protected enclosure and the whole of the enclosure designated a Controlled Area

D

7.2 Design of the CBCT room

7.2.1 Protection for adjacent areas

It is essential that shielding be provided to control dose in areas adjacent to the CBCT room. This is recognised in national guidance (HPA 2010a; HPA 2010b; Advies van de Hoge Gezondheidsraad, 2011; Statens strålevern 2010). Advice on the design of CBCT facilities has been published by the UK Health Protection Agency (HPA 2010a, HPA 2010b) and provides guidance for the qualified expert on aspects that must be considered when designing a dental CBCT facility.

The amount of scattered radiation per scan depends on a number of factors, and neither kV nor maximum FOV are good predictors of this. Furthermore, the dose distribution may not be uniform in all directions around the CBCT equipment. The HPA (HPA 2010a) report that the maximum scatter dose at a distance of 1m can range from 2 to 40 μGy per scan. Measurements carried out by SEDENTEXCT partners confirmed this range, although the majority of units gave readings between 6 to 12 μGy per scan. Detailed information, e.g. in the form of secondary radiation plots, should be sought from the supplier or manufacturer to allow the calculation of appropriate levels of shielding.

In calculating shielding, the workload of the unit also needs to be taken into consideration. For dental practice, the HPA (HPA 2010a) suggest that a workload of 20 scans per week be assumed, while for a hospital department the figure would be 50 scans per week. A review of workload within the SEDENTEXCT partners again confirms these assumptions as reasonable for current practice, although it must be born in mind that the clinical use of dental CBCT is still developing and workload assumptions should be kept under review.

Working to a dose constraint of 0.3 mSv per year to staff in adjacent areas, shielding up to 1.5mm lead equivalence will be required in the walls provided that the unit is positioned so that the distance to staff in the adjacent area is 1m or greater. However, due to the significant differences in maximum operating potential and levels of scattered radiation, many installations may be satisfactorily shielded with lower requirements. It is likely that doors, which will normally be further away from the unit, could contain less protection. In addition, floor and ceiling protection needs to be considered and it is likely that ground floor windows will need blocking up. A dose constraint of 0.3 mSv per year is in accord with Danish and UK requirements (Sundhedsstyrelsen 2009; HPA 2010b). Alternative national guidance exists but is in broad agreement with this. In Norway, a dose constraint of 0.25mSv per year is established, with shielding equivalent to 1mm lead considered satisfactory where equipment operates below 100kV. Where equipment operates at higher kiloVoltage, the Norwegian guidance recommends that it may be necessary to increase the protection to 3mm lead equivalent, depending on workload, room size and design and the frequency of use of neighbouring rooms. The input of the qualified expert in determining protection needs is advised (Statens strålevern, 2010).

The data in the table (7.1) below may be used for the purposes of initial cost estimates; however, each installation should be assessed on a case by case basis

with the input of a qualified expert and in the context of national guidelines and regulations.

Detailed information on the dose due to scattered radiation should be obtained to inform decisions about shielding requirements

D

Table 7.1: Summary of shielding requirements at 1 m for dose constraint of 0.3 mSv per annum

		Patients per week			
		5	10	25	50
Scatter per scan (μ Sv)	4	0.5 mm	0.5 mm	1.0 mm	1.0 mm
	8	0.5 mm	0.5 mm	1.0 mm	1.5 mm
	12	0.5 mm	1.0 mm	1.0 mm	1.5 mm
	16	0.5 mm	1.0 mm	1.5 mm	1.5 mm

7.2.2 Room layout

The operator position should be outside the room or, if inside, be provided with additional shielding in the form of a protective cubicle to stand behind. The position of the operator must always be such that they can clearly see the patient and the room entrance(s) and be able to interrupt the scan using the emergency stop, if required. This might be via a protected viewing window, a strategically positioned mirror or with the use of a CCTV camera. The emergency stop should be located adjacent to the operator, positioned so that the operator does not need to enter the room unprotected in order to activate it (HPA 2010 a, HPA 2010b).

For units requiring authorisation of the exposure from the computer software prior to exposure, it is essential that the computer should be located close to the X-ray unit rather than over a network to reduce the likelihood of the exposure being authorised without the operator at the CBCT control.

CBCT units usually require that the mains power supply be left on, to obviate the need for a lengthy warm up procedure before each exposure. If another unit is located in the same room, the layout should be arranged to reduce the likelihood of the wrong unit being initiated; for example, by providing exposure switches in separate locations or by placing the exposure switches in lockable boxes. Safeguards should also be incorporated into the exposure initiation systems to ensure that the equipment cannot be operated by people not authorised to do so. This can be achieved by the use of password or key control (HPA 2010a).

A system of warning lights is recommended for dental CBCT units, in line with local regulatory requirements for X-ray rooms; ideally providing a two stage indication: stage 1 to indicate readiness to expose (i.e. when the power is switched on to the unit) and stage 2 when X-rays are about to be or are being generated (HPA 2101b).

7.3 Personal Monitoring

Routine personal dosimetry for dental radiographic staff is generally considered desirable but not universally necessary across all European countries. (European Commission 2004). Given the higher dose levels when using dental CBCT units, the need for personal monitoring should be carefully considered, seeking the advice of a qualified expert if available.

Recent Belgian guidance recommends the routine use of personal dosimetry with dental CBCT (Advies van de Hoge Gezondheidsraad, 2011), while in Norway personal dosimetry is not required if the operator is always adequately protected by shielding (Statens strålevern, 2010). In the UK, the recommendation is for monitoring for an initial trial period and repeat one-off monitoring if the facilities, workload or techniques change, assuming that adequate protection is available for the operator. However, if the room design is such as to allow operation of the unit without being adequately shielded, continuous monitoring is advised. (HPA 2010a, HPA 2010b). The provision of monitoring for reassurance of pregnant staff should also be considered, although the dose to the foetus is likely to be significantly lower than the dose constraint of 1mSv during the term of pregnancy stated in the European Basic Safety Standards Directive (European Commission 1996).

The provision of Personal Monitoring should be considered

D

7.4 References

Advies van de Hoge Gezondheidsraad nr. 8705. Dentale Cone Beam Computed Tomography. Brussel: Hoge Gezondheidsraad, 2011. www.hgr-css.be

European Commission 2004. Radiation Protection 136. European Guidelines on Radiation Protection in Dental Radiology. Luxembourg: Office for Official Publications of the European Communities,. Available from: http://ec.europa.eu/energy/nuclear/radioprotection/publication/doc/136_en.pdf

European Commission 1996 Council Directive 96/29/Euratom of 13 May 1996 laying down basic safety standards for the protection of the health of workers and the general public against the dangers arising from ionizing radiation Official Journal of the European Communities L 159/1

HPA 2010a Recommendations for the design of X-ray facilities and quality assurance of dental Cone Beam CT (Computed tomography) systems HPA-RPD-065 JR Holroyd and A Walker Health Protection Agency

HPA 2010b Guidance on the Safe Use of Dental Cone Beam CT (computed tomography) Equipment
HPA-CRCE-010

Statens strålevern. Stråleverninfo 8:2010. Krav for bruk av Cone Beam CT ved odontologiske virksomheter. Østerås: Statens strålevern, 2010.

Sundhedsstyrelsen. Statens Institut for Strålebeskyttelse. Krav til 3D dental. Herlev: Statens Institut for Strålebeskyttelse, 2009.

8: ECONOMIC EVALUATION

Economic evaluation attempts to weigh costs and effects of alternative interventions with the goal that available resources are used to achieve maximum benefits for patients in terms of health and quality of life. In emerging technologies, this is particularly important to avoid inappropriate and excessive use. As part of the systematic review process described in this document, no literature was identified that fell under the heading “cost effectiveness” or “economic evaluation”. A few studies mentioned the costs of CBCT, usually quoting the hospital fee for a CBCT examination. Such figures do not usually reflect real costs and reflect idiosyncrasies of particular hospitals and healthcare systems.

As part of the SEDENTEXCT project, the Malmö University partner has led the research on health economic evaluation and has commenced a broader systematic review to analyse evidence on economic evaluation in oral health care, particularly as relates to diagnostic methods. Studies identified by literature search were interpreted by two reviewers using a check-list for assessing economic evaluations (Drummond et al. 2005). Of four publications presenting diagnostic interventions in oral health care, only one publication remained after the reviewers’ interpretation. This publication (Norlund et al. 2009) presented a model analysis of the cost of true-positive occlusal dentine caries detection in permanent molars assessed by different diagnostic strategies using bitewing radiography. Thus, no publication that presented an economic evaluation of CBCT was identified with the aid of the systematic review.

At the time of writing, cost analysis carried out within the project is unpublished. There are data on cost-analysis collected from examinations of maxillary canines with eruption disturbances that shows that CBCT is more costly than conventional examinations with intraoral and panoramic radiography. A comparison of costs of CBCT-examinations within different health care systems of patients with different clinical conditions showed that estimates for costs varied for examination of one and the same condition between the health care systems. Thus, valuation of costs in monetary terms of CBCT should not be generalized from one health care system to another but a model for cost analysis similar to that designed within the project provides an important tool for economic evaluations in comparing costs and consequences of diagnostic methods and can guide planning of service delivery in both public and private sectors. Considering the results obtained, the use of CBCT needs to involve a comprehensive assessment of economic factors in conjunction with radiation dosage, diagnostic accuracy efficacy and the benefits for the patients in terms of health and life quality in different health care contexts.

*Economic evaluation of CBCT should be a part of
assessment of its clinical utility*

GP

8.1 References

Drummond MF, Sculpher MJ, Torrance GW, O'Brien BJ, Stoddart GL. Methods for the economic evaluation of health care programmes. Oxford: Oxford Medical Publications, 3rd ed, 2005.

Norlund A, Axelsson S, Dahlén G, Espelid I, Mejåre I, Tranaeus S, Twetman S. Economic aspects of the detection of occlusal dentine caries. *Acta Odontol Scand* 2009;67:38-43.

Christell H, Birch S, Horner K, Rohlin M, Lindh C, The SEDENTEXCT consortium. A model for cost-analysis of diagnostic methods in oral health care. An application comparing a new imaging technology with a conventional one for maxillary canines with eruption disturbances. Submitted to *Community Dentistry and Oral Epidemiology* 2010.

9: TRAINING

9.1 Roles and responsibilities

As defined in the European Directive (Council Directive 97/43/Euratom, 1997), the roles involved in delivering a diagnostic radiological service to patients are:

The Holder: any natural or legal person who has the legal responsibility under national law for a given radiological installation.

The Prescriber: a medical doctor, dentist or other health professional, who is entitled to refer individuals for medical exposure to a practitioner, in accordance with national requirements. The prescriber is involved in the justification process at the appropriate level.

The Practitioner: a medical doctor, dentist or other health professional, who is entitled to take clinical responsibility for an individual medical exposure in accordance with national requirements.

The medical physics expert (MPE): an expert in radiation physics or radiation technology applied to exposure, within the scope of the Directive, whose training and competence to act is recognized by the competent authorities; and who, as appropriate, acts or gives advice on patient dosimetry, on the development and use of complex techniques and equipment, on optimization, on quality assurance, including QC, and on other matters relating to radiation protection, concerning exposure within the scope of the Directive.

In hospital practice, these roles are usually straightforward to link to particular individuals; the Holder is the Hospital or Health Service Authority, the Prescriber is the health professional carrying out the patient's clinical care, the Practitioner is usually a radiologist and a MPE is appointed to provide specialist support. In primary dental care, however, the first three of these roles are frequently held by one individual. "Self referral", where the dentist is both Prescriber and Practitioner, is normal. An MPE may, or may not, be normally appointed to a dental practice depending on national regulations.

In addition to these roles, the practical aspects for the procedure, or part of it, may be delegated by the holder of the radiological installation or the practitioner, as appropriate, to one or more individuals entitled to act in this respect in a recognized field of specialization. In hospital practice, this may include a radiographer/ imaging technician, but in primary dental care it may involve the dentist or a dental assistant/ nurse. In the current document, any role involved in practical aspects for the procedure will be referred to by the term "Operator".

The Directive requires that Member States shall ensure that practitioners and the other individuals mentioned above have adequate theoretical and practical training for the purpose of radiological practices, as well as relevant competence in radiation protection. Where a relatively new technology such as CBCT is concerned, the Panel recognized that existing training of users may be less than ideal and that appropriate arrangements for training must be made. As stated in Section 3 of this document, this is considered a "Basic Principle" of the use of CBCT in dentistry.

All those involved with CBCT must have received adequate theoretical and practical training for the purpose of radiological practices and relevant competence in radiation protection

ED BP

A key part of continuing education and training is identification of those most capable of delivering it. Specialists in Dental and Maxillofacial Radiology, with their unique combination of a dental and a radiological training, are likely to be the most appropriate individuals to deliver much of the training, in conjunction with medical physicist support.

Continuing education and training after qualification are required, particularly when new CBCT equipment or facilities are adopted

BP

Dentists and dental specialists responsible for CBCT facilities who have not previously received “adequate theoretical and practical training” should undergo a period of additional theoretical and practical training that has been validated by an academic institution (University or equivalent). Where national specialist qualifications in Dental and Maxillofacial Radiology exist, the design and delivery of CBCT training programmes should involve a Dental and Maxillofacial Radiologist

BP

9.2 Curricula for training in CBCT

While the content of training programmes aimed at delivering “adequate theoretical and practical training” are most appropriately determined nationally within Member States, the Guideline Development Panel involved in devising the “Basic Principles” of the use of CBCT in dentistry (Horner et al, 2009) endorsed a draft core curriculum to provide a basic structure and content for training (Table 9.1). The Guideline Development Panel recognised the large national variation in Europe in the clinical services provided by dentists in primary care.

Table 9.1: Appendix to the EADMFR Basic Principles on the use of Cone Beam CT, outlining “adequate theoretical and practical training” for dentists using CBCT. Adapted from Horner et al, 2009.

Role	Training content
The Prescriber: a dentist referring a patient for CBCT and receiving images for clinical use	<p>Theoretical instruction</p> <ul style="list-style-type: none"> • Radiation physics in relation to CBCT equipment • Radiation doses and risks with CBCT • Radiation protection in relation to CBCT equipment, including justification (referral/ selection criteria) and relevant aspects of optimisation of exposures • CBCT equipment and apparatus <p>Radiological interpretation</p> <ul style="list-style-type: none"> • Principles and practice of interpretation of dento-alveolar CBCT images of the teeth, their supporting structures, the mandible and the maxilla up to the floor of the nose (e.g. 8cm x 8cm or smaller fields of view) • Normal radiological anatomy on CBCT images • Radiological interpretation of disease affecting the teeth and jaws on CBCT images • Artefacts on CBCT images
The Practitioner: a dentist responsible for performing CBCT examinations	<p>Theoretical instruction</p> <ul style="list-style-type: none"> • Radiation physics in relation to CBCT equipment • Radiation doses and risks with CBCT • Radiation protection in relation to CBCT equipment, including justification (referral/ selection criteria), optimisation of exposures and staff protection • CBCT equipment and apparatus • CBCT image acquisition and processing <p>Practical instruction</p> <ul style="list-style-type: none"> • Principles of CBCT imaging • CBCT equipment • CBCT imaging techniques • Quality assurance for CBCT • Care of patients undergoing CBCT <p>Radiological interpretation</p> <ul style="list-style-type: none"> • Principles and practice of interpretation of dento-alveolar CBCT images of the teeth, their supporting structures, the mandible and the maxilla up to the floor of the nose (e.g. 8cm x 8cm or smaller fields of view) • Normal radiological anatomy on CBCT images • Radiological interpretation of disease affecting the teeth and jaws on CBCT images • Artefacts on CBCT images

In parallel, or subsequently, guidelines on dental CBCT have been developed nationally in Belgium (Advies van de Hoge Gezondheidsraad, 2011), Denmark (Sundhedsstyrelsen, 2009), France (Haute Autorité de Santé, 2009), Germany (Leitlinie der DGZMK, 2009; Schulze & Schulze, 2006), Norway (Statens strålevern, 2010) and the United Kingdom (Health Protection Agency, 2010). These incorporate

recommendations for training in varying detail. Authorities in other European countries are in the process of developing their own national guidelines.

In France, the relevant “Basic Principles”, Nos.16-20 (Section 3) have been reiterated (Haute Autorité de Santé, 2009). In Norway, the emphasis is placed upon “relevant and documented competence” in radiological interpretation, in physics and in operating equipment. It is a requirement in Norway that a radiologist is employed by a dental practice carrying out CBCT examinations, but that limited volume CBCT (definition as given in Table 9.1 and in Basic Principle No.19 in Section 2) can be interpreted by a dentist with relevant and documented competence if the radiologist allows it (Statens strålevern, 2010). The need for training so that competence is achieved is therefore implicit.

More detailed training curricula have been devised in Denmark, Germany and the UK. In the Danish guidance, the dentist responsible must have the supplementary training needed to interpret the CBCT images, while all personnel who work the units must have instructions on how to operate them. The requirements for training include a practical course with training of the responsible dentist and personnel on how to operate the units and also further education of the responsible dentist in the theoretical background for CBCT imaging. The German course concept includes supervised practical training in interpretation, theoretical training, personal study and an examination. The UK guidance document includes a detailed curriculum for theoretical training which differentiates between the training needs of those in Prescriber, Practitioner and Operator roles, and which recommends supplementary training in operating CBCT equipment ideally given by a trained applications specialist from the equipment manufacturer. The recommended duration of training in these national guideline documents varies considerably.

In the light of these differing national developments in training curricula, and recognising the widely varying traditions in different countries, the Panel concluded that it was inappropriate to recommend a more detailed curriculum than that described in Table 9.1. National authorities should build upon this “core” curriculum in a manner which satisfies their specific needs.

There is no comparable curriculum or guidance for medical physics experts on the specific training needs for CBCT. It is clear that a MPE will have substantial existing knowledge, but that CBCT has some unique characteristics that necessitate additional training. While this training might be obtained by self-study, consideration should be given to developing CBCT learning opportunities for MPEs so that they can familiarise themselves with the specific requirements.

The role that has not been addressed above is the training of equipment manufacturers and suppliers, particularly of applications specialists who may contribute themselves to training of dentists and dental staff. Their recommendations to the CBCT user on exposure and optimization are of critical importance in determining future day-to-day practices of the CBCT Operators. The Panel believes that the training needs of this stakeholder group should not be ignored. The content of training should be based upon the theoretical content of the curriculum outlined in Table 9.1, with the addition of elements of dental terminology and radiological interpretation which will allow an understanding of clinical needs and more effective

communication with clinical staff. The Panel suggest that core training could be delivered in the equivalent of 4 hours.

CBCT applications specialists and agents of manufacturers and suppliers of CBCT equipment who provide information and training to clinical staff should obtain relevant training in radiation protection and optimization

GP

9.3 References

Advies van de Hoge Gezondheidsraad nr. 8705. Dentale Cone Beam Computed Tomography. Brussel: Hoge Gezondheidsraad, 2011. www.hgr-css.be

Council Directive 97/43/Euratom of 30 June 1997 (on health protection of individuals against the dangers of ionizing radiation in relation to medical exposure).

Haute Autorité de Santé. Tomographie Volumique a Faisceau Conique de la Face (Cone Beam Computerized Tomography). Rapport d'évaluation Technologique. Service évaluation des actes professionnels. Saint-Denis La Plaine: Haute Autorité de Santé, 2009. <http://www.has-sante.fr>

Health Protection Agency. Guidance on the Safe Use of Dental Cone Beam CT (Computed Tomography) Equipment. HPA-CRCE-010. Chilton: Health Protection Agency, 2010.

Horner K, Islam M, Flygare L, Tsiklakis T, Whaites E. Basic Principles for Use of Dental Cone Beam CT: Consensus Guidelines of the European Academy of Dental and Maxillofacial Radiology. *Dentomaxillofac Radiol* 2009; 38: 187-195.

Leitlinie der DGZMK. Dentale Volumentomographie (DVT) - S1 Empfehlung. *Deutsche Zahnärztliche Zeitschrift* 64, 2009: 490 - 496.

Schulze D, Schulze R. Kurskonzept zur Vermittlung der Fachkunde der dentalen digitalen Volumentomographie für Neuanwender. 2006 [Personal Communication].

Statens strålevern. Stråleverninfo 8:2010. Krav for bruk av Cone Beam CT ved odontologiske virksomheter. Østerås: Statens strålevern, 2010.

Sundhedsstyrelsen. Statens Institut for Strålebeskyttelse. Krav til 3D dental. Herlev: Statens Institut for Strålebeskyttelse, 2009.

APPENDIX 1 SUMMARY OF RECOMMENDATIONS

The core recommendations and statements in this document are the “Basic Principles”, described in section 3.3 (page 27). Below are listed the other specific guidelines, taken from the relevant sections, with their evidence grading:

Introduction and Guideline development

1.1: These Guidelines should be reviewed and renewed using an evidence-based methodology after a period no greater than five years after publication.

GP

Justification and referral criteria

4.1: All CBCT examinations must be justified on an individual basis by demonstrating that the potential benefits to the patients outweigh the potential risks. CBCT examinations should potentially add new information to aid the patient’s management. A record of the Justification process must be maintained for each patient.

ED BP

4.2: CBCT should not be selected unless a history and clinical examination have been performed. “Routine” or “screening” imaging is unacceptable practice.

ED BP

4.3: When referring a patient for a CBCT examination, the referring dentist must supply sufficient clinical information (results of a history and examination) to allow the CBCT Practitioner to perform the Justification process

ED BP

4.4: For the localised assessment of an impacted tooth (including consideration of resorption of an adjacent tooth) where the current imaging method of choice is MSCT, CBCT may be preferred because of reduced radiation dose.

GP

4.5: CBCT may be indicated for the localised assessment of an impacted tooth (including consideration of resorption of an adjacent tooth) where the current imaging method of choice is conventional dental radiography and when the information cannot be obtained adequately by lower dose conventional (traditional) radiography.

C

4.6: For the localised assessment of an impacted tooth (including consideration of resorption of an adjacent tooth), the smallest volume size compatible with the situation should be selected because of reduced radiation dose. The use of CBCT units offering only large volumes (craniofacial CBCT) requires very careful justification and is generally discouraged.

GP BP

4.7: Where the current imaging method of choice for the assessment of cleft palate is MSCT, CBCT may be preferred if radiation dose is lower. The smallest volume size compatible with the situation should be selected because of reduced radiation dose.

GP

4.8: CBCT is not normally indicated for planning the placement of temporary anchorage devices in orthodontics.

GP

4.9: Large volume CBCT should not be used routinely for orthodontic diagnosis.

D

4.10: For complex cases of skeletal abnormality, particularly those requiring combined orthodontic/surgical management, large volume CBCT may be justified in planning the definitive procedure, particularly where MSCT is the current imaging method of choice.

GP

4.11: Research is needed to define robust guidance on clinical selection for large volume CBCT in orthodontics, based upon quantification of benefit to patient outcome.

GP

4.12: CBCT is not indicated as a method of caries detection and diagnosis.

B

4.13: CBCT is not indicated as a routine method of imaging periodontal bone support.

C

4.14: Limited volume, high resolution CBCT may be indicated in selected cases of infra-bony defects and furcation lesions, where clinical and conventional radiographic examinations do not provide the information needed for management.

C

4.15: Where CBCT images include the teeth, care should be taken to check for periodontal bone levels when performing a clinical evaluation (report).

GP

4.16: CBCT is not indicated as a standard method for identification of periapical pathosis.

GP

4.17: Limited volume, high resolution CBCT may be indicated for periapical assessment, in selected cases, when conventional radiographs give a negative finding when there are contradictory positive clinical signs and symptoms.

GP

4.18: Where CBCT images include the teeth, care should be taken to check for periapical disease when performing a clinical evaluation (report).

GP

4.19: CBCT is not indicated as a standard method for demonstration of root canal anatomy.

GP

4.20: Limited volume, high resolution CBCT may be indicated, for selected cases where conventional intraoral radiographs provide information on root canal anatomy which is equivocal or inadequate for planning treatment, most probably in multi-rooted teeth.

GP

4.21: Limited volume, high resolution CBCT may be indicated for selected cases when planning surgical endodontic procedures. The decision should be based upon potential complicating factors, such as the proximity of important anatomical structures.

GP

4.22: Limited volume, high resolution CBCT may be indicated in selected cases of suspected, or established, inflammatory root resorption or internal resorption, where three-dimensional information is likely to alter the management or prognosis of the tooth.

D

4.33: Limited volume, high resolution CBCT may be justifiable for selected cases, where endodontic treatment is complicated by concurrent factors, such as resorption lesions, combined periodontal/endodontic lesions, perforations and atypical pulp anatomy.

C

4.34: Limited volume, high resolution CBCT is indicated in the assessment of dental trauma (suspected root fracture) in selected cases, where conventional intraoral radiographs provide inadequate information for treatment planning.

B

4.35: Where conventional radiographs suggest a direct inter-relationship between a mandibular third molar and the mandibular canal, and when a decision to perform surgical removal has been made, CBCT may be indicated.

C

4.36: CBCT may be indicated for pre-surgical assessment of an unerupted tooth in selected cases where conventional radiographs fail to provide the information required.

GP

4.37: CBCT is indicated for cross-sectional imaging prior to implant placement as an alternative to existing cross-sectional techniques where the radiation dose of CBCT is shown to be lower.

D

4.38: For cross-sectional imaging prior to implant placement, the advantage of CBCT with adjustable fields of view, compared with MSCT, becomes greater where the region of interest is a localised part of the jaws, as a similar sized field of view can be used.

GP

4.39: Where it is likely that evaluation of soft tissues will be required as part of the patient's radiological assessment, the appropriate initial imaging should be MSCT or MR, rather than CBCT.

BP

4.40: Limited volume, high resolution CBCT may be indicated for evaluation of bony invasion of the jaws CBCT by oral carcinoma when the initial imaging modality used for diagnosis and staging (MR or MSCT) does not provide satisfactory information.

D

4.41: For maxillofacial fracture assessment, where cross-sectional imaging is judged to be necessary, CBCT may be indicated as an alternative imaging modality to MSCT where radiation dose is shown to be lower and soft tissue detail is not required.

D

4.42: CBCT is indicated where bone information is required, in orthognathic surgery planning, for obtaining three-dimensional datasets of the craniofacial skeleton.

C

4.43: Where the existing imaging modality for examination of the TMJ is MSCT, CBCT is indicated as an alternative where radiation dose is shown to be lower.

B

CBCT equipment factors in the reduction of radiation risk to patients.

5.1: Kilovoltage and mAs should be adjustable on CBCT equipment and must be optimised during use according to the clinical purpose of the examination, ideally by setting protocols with the input of a medical physics expert.

B

5.2: Multipurpose dental CBCT equipment should offer a choice of volume sizes and examinations must use the smallest that is compatible with the clinical situation if this provides less radiation dose to the patient.

B BP

5.3: Research studies on optimisation of filtration for dental CBCT units should be performed.

GP

5.4: Dental CBCT units equipped with either flat panel detectors or image intensifiers need to be optimised in terms of dose reduction before use.

GP

5.5: Multipurpose dental CBCT equipment should offer a choice of voxel sizes and examinations should use the largest voxel size (lowest dose) consistent with acceptable diagnostic accuracy.

C

5.6: Research studies should be performed to assess further the effect of the number of projections on image quality and radiation dose.

GP

5.7: Shielding devices could be used to reduce doses to the thyroid gland where it lies close to the primary beam. Care is needed in positioning so that repeat exposure is not required. Further research is needed on effectiveness of such devices in dose reduction.

GP

Quality standards and quality assurance

6.1: Published equipment performance criteria should be regularly reviewed and revised as greater experience is acquired in testing dental CBCT units.

GP

6.2: Testing of dental CBCT should include a critical examination and detailed acceptance and commissioning tests when equipment is new and routine tests throughout the life of the equipment. Testing should follow published recommendations and a medical physics expert should be involved.

ED BP

6.3: Manufacturers of dental CBCT equipment should provide a read-out of Dose-Area-Product (DAP) after each exposure.

D

6.4: Until further audit data is published, the panel recommend the adoption of an achievable Dose Area Product of 250 mGy cm^2 for CBCT imaging for the placement of an upper first molar implant in a standard adult patient.

D

6.5: Assessment of the clinical quality of images should be a part of a quality assurance programme for CBCT.

GP

6.6: Establishments carrying out CBCT examinations should perform reject analysis, either prospectively or as part of retrospective clinical audit, at intervals no greater than once every six months.

GP

6.7: As a minimum target, no greater than 5% of CBCT examinations should be classified as “unacceptable”. The aim should be to reduce the proportion of unacceptable examinations by 50% in each successive audit cycle.

GP

6.8: Image quality criteria should be developed for dental CBCT, ideally at the European level.

GP

Staff protection

7.1: It is essential that a qualified expert is consulted over the installation and use of CBCT to ensure that staff dose is as low as reasonably achievable and that all relevant national requirements are met.

ED D

7.2: CBCT equipment should be installed in a protected enclosure and the whole of the enclosure designated a Controlled Area.

D

7.3: Detailed information on the dose due to scattered radiation should be obtained to inform decisions about shielding requirements.

D

7.4: The provision of Personal Monitoring should be considered.

D

Economic evaluation

8.1: Economic evaluation of CBCT should be a part of assessment of its clinical utility.

GP

Training

9.1: All those involved with CBCT must have received adequate theoretical and practical training for the purpose of radiological practices and relevant competence in radiation protection.

ED BP

9.2: Continuing education and training after qualification are required, particularly when new CBCT equipment or facilities are adopted.

BP

9.3: Dentists and dental specialists responsible for CBCT facilities who have not previously received “adequate theoretical and practical training” should undergo a period of additional theoretical and practical training that has been validated by an academic institution (University or equivalent). Where national specialist qualifications in Dental and Maxillofacial Radiology exist, the design and delivery of CBCT training programmes should involve a Dental and Maxillofacial Radiologist.

BP

9.4: CBCT applications specialists and agents of manufacturers and suppliers of CBCT equipment who provide information and training to clinical staff should obtain relevant training in radiation protection and optimization.

GP

APPENDIX 2 RECOMMENDATIONS FOR RESEARCH AND DEVELOPMENT

An intention of the SEDENTEXCT project was that these guidelines would be used to identify gaps in research. By doing this, encouragement could be given to the development of subsequent research projects which will be formative in the update of future evidence-based guidelines for the use of dental CBCT.

A number of important gaps in the evidence became evident to the Panel during the review process. These are reflected in some guideline statements within the document (recommendations 4.11, 5.3, 5.6, 5.7 and 6.8 in Appendix 1). In addition, the review highlighted the need for more dose audit data to enable the setting of suitable DRLs for CBCT examinations.

The key priorities identified by the project team include:

1. Randomised clinical trials of CBCT versus conventional radiography, looking at the higher levels of diagnostic efficacy, notably Outcome Efficacy, and incorporating economic evaluation. The highest priority area is the use of large volume CBCT in orthodontics.
2. Research to relate image quality to diagnostic tasks, leading to the development of objective and clinical image quality criteria for dental CBCT examinations.
3. Patient dose optimization studies, notably in filtration, exposure factor reduction (mAs, kV and number of basis images) and the need for thyroid shielding.

The SEDENTEXCT Workshop 31st March 2011

Beyond this, however, an intrinsic objective of the SEDENTEXCT project was to involve stakeholders as much as possible in guideline setting and in making recommendations. On March 31st 2011, a SEDENTEXCT Workshop on dental CBCT was held in Leeds, UK, under the auspices of the British Society of Dental and Maxillofacial Radiology. Over 100 participants were present from across Europe, including dental radiologists, medical physicists, national regulatory or advisory bodies and equipment manufacturers and representatives. As part of the programme, time was set aside for a “break out” session with the participants divided into ten working groups, followed by a plenary meeting. The groups were asked to elect a spokesperson and each group included at least one SEDENTEXCT project scientist. Each group was asked to consider one of two questions, to summarise their recommendations and to bring them to the plenary meeting. Half of the working groups addressed question 1 and half question 2:

1. *“What do you think should be the priorities for research in dental CBCT in the immediate future?”*
2. *“What developments in the design and function of CBCT machines would be of most benefit in the next five years?”*

Feedback from participants was recorded and collated after the Workshop and are presented below. In each case, the recommendations are presented in priority order, reflecting the frequency of comments recorded.

Priorities for research in dental CBCT

The following constitute the recommendations for research recorded at the Workshop:

- Clinical trials of patient clinical outcomes when using CBCT compared with conventional x-rays
- Clinical trials of CBCT-based diagnosis/treatment planning versus conventional imaging
- Research on the need for CBCT prior to third molar extraction
- Research on clinical pathways to identify situations where preliminary conventional radiographs can be omitted
- Research on image quality requirements for different clinical applications
- Research on identifying minimum equipment performance standards

It is notable that this list accords well with the research priorities identified by the SEDENTEXCT team.

Developments in CBCT equipment design and function

The following seven items were recorded with a high frequency:

- Metal (dental restoration related) artefact reduction software/ algorithms need to be developed
- Need for variable size of FOVs/ FOVs to fit with diagnostic tasks/ wider choice of FOVs/ flexibility/ even smaller volume options
- Dose indicator/ DAP readout on CBCT equipment should be available and standardised across manufacturers
- Automatic exposure control
- Optimisation/ further dose reduction strategies incorporated
- Simple imaging protocols for dentists/presets for specific clinical applications
- An increase resolution without an increase in dose

Other comments were received but with lower frequency, including:

- Improvement in soft tissue contrast
- Reconstruction algorithms optimised to the clinical purpose of the examination
- Flexibility for different tasks
- Easier localisation of small FOV
- Improved patient positioning aids
- Better head support to prevent movement and allow patients with positioning challenges (e.g spinal deformity)
- International standard for design of CBCT equipment

- User access to exposure settings to permit optimisation
- QA software integrated into equipment
- Better training
- DICOM compatibility (allowing 3d model production)
- More intuitive software
- Ordinary dentist/ hospital practitioner systems need to be different
- Less variation in machines – too much choice now
- Machines with panoramic option should have field size limitation facilities

We hope that the feedback from the Workshop on priorities for development in equipment design and function will be of interest and value to manufacturers in the years ahead. The SEDENTEXCT team are very grateful to the participants at the Workshop for their contributions.

APPENDIX 3 GLOSSARY AND ABBREVIATIONS

A (evidence grade)	At least one meta analysis, systematic review, or RCT rated as 1++, and directly applicable to the target population; or a systematic review of RCTs or a body of evidence consisting principally of studies rated as 1+, directly applicable to the target population, and demonstrating overall consistency of results
AMA	Active matrix array
B (evidence grade)	A body of evidence including studies rated as 2++, directly applicable to the target population, and demonstrating overall consistency of results; or extrapolated evidence from studies rated as 1++ or 1+
BP (evidence grade)	Basic Principle. Consensus principle of the European Academy of Dental and Maxillofacial Radiology (section 3).
GP (evidence grade)	Good Practice (based on clinical expertise of the guideline group and subsequent consensus of stakeholders)
C (evidence grade)	A body of evidence including studies rated as 2+, directly applicable to the target population and demonstrating overall consistency of results; or extrapolated evidence from studies rated as 2++
CBCT	Cone Beam Computed Tomography
Controlled area	An area subject to special rules for the purpose of protection against ionizing radiation and to which access is controlled.
Craniofacial CBCT	Definition based on field of view size. "Craniofacial" fields of view have a height which is greater than 10cm, allowing maxillofacial imaging. This is synonymous with "Large volume CBCT" (<i>vide infra</i>).
CTDI	Computed tomography dose index
D (evidence grade)	Evidence level 3 or 4; or extrapolated evidence from studies rated as 2+
DAP	Dose-Area-Product
Dento-alveolar CBCT	Definition based on field of view size. "Dento-alveolar" fields of view have a height smaller than 10cm, suitable for imaging the lower and upper jaws, but are often substantially smaller than this.
DICOM	The Digital Imaging and Communications in Medicine (DICOM) standard
DMFR	Dento Maxillo Facial Radiology
Dose constraint	A restriction on the prospective doses to individuals which may result from a defined source, for use at the planning stage in radiation protection whenever optimization is involved.

DRLs	Diagnostic Reference Levels: dose levels in medical radiodiagnostic practices for typical examinations for groups of standard-sized patients or standard phantoms for broadly defined types of equipment. These levels are expected not to be exceeded for standard procedures when good and normal practice regarding diagnostic and technical performance is applied.
DVT	Digital Volumetric Tomography
EADMFR	European Academy of Dento Maxillo Facial Radiology
EAO	European Association for Osseointegration
ED (evidence grade)	Derived from the EC Council Directives 96/29/Euratom or 97/43/Euratom.
Effective dose	The sum of the weighted equivalent doses in all the tissues and organs of the body specified by ICRP from internal and external irradiation.
FOV	Field of view
FDI	Federation Dentaire Internationale
FPD	Flat panel detector
High resolution CBCT	In the context of the current document, the use of voxel sizes of 0.2mm or smaller.
Holder	Any natural or legal person who has the legal responsibility under national law for a given radiological installation.
HU	Hounsfield Unit
ICRP	International Commission on Radiological Protection
II	Image intensifier
kV	kiloVoltage
Large volume CBCT	CBCT in which the field of view is larger than the jaws (mandible and maxilla). Typically this refers to fields of view which encompass the facial bones and base or skull or larger. This is synonymous with “craniofacial CBCT” (<i>vide supra</i>).
Limited volume CBCT	CBCT in which the field of view is limited to a volume smaller than the jaws (mandible and maxilla). Typically this refers to small fields of view suitable for imaging one, or a few, teeth.
Medical physics expert	An expert in radiation physics or radiation technology applied to exposure whose training and competence to act is recognized by the competent authorities; and who, as appropriate, acts or gives advice on patient dosimetry, on the development and use of complex techniques and equipment, on optimization, on quality assurance, including quality control, and on other matters relating to radiation protection, concerning exposure within the scope of Council Directive 97/43 Euratom of 30 June 1997.
MPE	Medical physics expert
MSCT	Multislice computed tomography. MSCT refers to “conventional medical CT”
Pixel	Picture (two-dimensional) element
QA; Quality Assurance	All those planned and systematic actions necessary to provide adequate confidence that a structure, system,

	component or procedure will perform satisfactorily complying with agreed standards.
Quality Control	A part of quality assurance. The set of operations (programming, coordinating, implementing) intended to maintain or to improve quality. It covers monitoring, evaluation and maintenance at required levels of all characteristics of performance of equipment that can be defined, measured, and controlled.
QUADAS	A tool for the quality assessment of studies of diagnostic accuracy included in systematic reviews.
Qualified expert	Person having the knowledge and training needed to carry out physical, technical or radiochemical tests enabling doses to be assessed, and to give advice in order to ensure effective protection of individuals and the correct operation of protective equipment, whose capacity to act as a qualified expert is recognized by the competent authorities. A qualified expert may be assigned the technical responsibility for the tasks of radiation protection of workers and members of the public
SEDEXCT	Safety and Efficacy of a New and Emerging Dental X-ray Modality. A project co-funded by the European Atomic Energy Community's Seventh Framework Programme (Euratom FP7, 2007-11 under grant agreement no. 212246 (SEDEXCT)).
SIGN	Scottish Intercollegiate Guidelines Network
STARD	S tandards for the R eporting of D iagnostic Accuracy Studies
Sv	The special name of the unit of equivalent or effective dose. One sievert is equivalent to one joule per kilogram: $1 \text{ Sv} = 1 \text{ J kg}^{-1}$.
TFT	Thin film transistor
TLD	Thermoluminescent dosimeter
TMJ	Temporomandibular joint
Voxel	Volume (three-dimensional) element

APPENDIX 4 QUALITY CONTROL MANUAL FOR DENTAL CBCT SYSTEMS

1 Introduction

A Quality Control Programme lays out the necessary testing to ensure that all parameters during the examination procedure are in accordance with the standard operating protocol, thus resulting in images with diagnostic value, without exposing the patient to unnecessary risk.

A programme of equipment tests for dental cone beam CT should consider the following aspects:

- Performance of the X-ray tube and generator
- Patient dose
- Quantitative assessment of image quality
- Display screen performance

Such a programme is a requirement of the European Union Medical Exposures Directiveⁱ as part of the optimisation process to ensure patient dose is as low as reasonably practicable whilst achieving clinically adequate image quality. Any practice undertaking medical exposure should have access to the advice of a medical physics expert on such matters. The Medical Exposures Directive is currently under revisionⁱⁱ and the role of the medical physics expert is given higher prominence in the most recent draft.

Testing and patient dose assessment is carried out when the equipment is first installed as part of the commissioning process and then throughout the life of the equipmentⁱⁱⁱ. This protocol outlines those physical tests and measurements that are considered to be part of a standard quality control programme for a dental CBCT unit. It does not cover quality assurance of the clinical image.

A range of tests are appropriate for dental CBCT looking at different aspects of the equipment and image display. National guidance exists in some EU countries^{iv} and the SEDENTEXCT project^v has developed phantoms to facilitate carrying out a wide range of measurements. Some of the tests are straightforward and can be readily performed by the clinical staff using the CBCT equipment. Other tests are more complex and the input of a medical physicist is required.

Routine quality control tests primarily involve comparison of results with those determined during commissioning. Significant variation, as indicated by pre-determined action levels, should be investigated, either with the help of a medical physics expert or the equipment service engineer.

Not all possible methods of assessment are considered essential. It is important to perform enough tests to confirm that the equipment is operating as intended. More complex tests do add extra information that is helpful in the optimisation process and they are detailed here for completeness. However, whether the more detailed tests are undertaken will depend on the availability of expert support and the necessary resources.

The tests are summarised in the table at the end of the manual. The recommendations of priority, level of expertise, frequency and action levels are based on published guidance^v and the experience of the SEDENTEXCT team in validating the use of the SEDENTEXCT QC test phantom. This represents an initial assessment of what is sensible and achievable but it must be borne in mind that, as experience of testing these units is obtained over a period of years, these recommendations should be critically reviewed as new evidence becomes available.

Some manufacturers of dental CBCT systems provide a quality assurance phantom with their system, which should come with recommendations on the tests that should be performed, the best way to perform them, how often they should be performed and how the results should be interpreted. Some of these quality assurance phantoms are also provided with software that automatically performs analysis of the acquired image.

Where a phantom has been supplied, the manufacturer's recommendations are likely to be broadly similar to those contained within this manual. Where there are some tests that are included in the manufacturer's recommendations but not in this manual, they should be performed as there may be a specific reason for its inclusion. Where a test is included in this manual but not in the manufacturer's recommendations, consideration should be given to performing the test. Consult a medical physicist if necessary.

2 X-ray tube and generator

The correct and reliable performance of the X-ray tube and generator is crucial to the production of consistent images. Both radiation output and tube kilovoltage should be regularly monitored whilst tube filtration and leakage should be performed as part of the equipment commissioning and should be repeated if major repair work is carried out on the tube head.

2.1 Radiation output

This is assessed by measuring the absorbed dose in air at a fixed point in the X-ray beam, e.g. by using a small thimble ionisation chamber placed at the isocentre. It should be noted that the ionisation chamber should have isotropic sensitivity.

2.1.1 Radiation Output Repeatability

This test monitors the consistency of the radiation output for a series of radiation exposures using constant exposure parameters.

Example: Repeat five measurements using constant exposure parameters at a typical clinical setting.

2.1.2 Radiation Output Reproducibility

This test monitors the effect of the exposure parameters (tube voltage and mAs) on the radiation output. Comparison should be made with the baseline values established at commissioning.

Example: Measure at a range of tube voltages e.g. 70, 80, 90kV_p at a range of typical clinical mAs settings.

Note: Many CBCT units do not allow a manual selection of tube voltages and mAs. For these units, the above exposures should be made at the automatically selected exposure settings.

2.2 Tube potential

The voltage applied to the X-ray tube determines the energy of the X-ray photons and is a major factor in determining the contrast in the image.

Assessment of the tube potential ensures that the delivered kV_p is close to that set on the unit by the operator. Poor agreement between the two would affect clinical image quality, equipment radiation output and patient dose.

2.2.1 kV accuracy

The kV_p should be measured directly using a kV divider device at intervals of 10kV_p across the full range the unit is capable of producing.

2.2.2 kV repeatability

The consistency of the tube potential should be monitored by repeating five measurements at at least two clinically relevant kV_p values, where possible.

2.2.3 kV reproducibility

The reproducibility of the tube potential over time should be monitored by comparing the measured results for kV_ps at intervals of 10kV across the full range the unit can produce with those established as baseline values at commissioning.

2.3 Filtration

The filtration of an X-ray tube absorbs the low energy photons that do not contribute to the image formation but do contribute to patient skin dose. Having adequate filtration is essential to ensure that patient dose is controlled. The total filtration should be marked on the X-ray tube housing.

Total filtration can be estimated by measuring the Half-Value Layer (HVL). The HVL is the thickness of the absorber required to reduce the intensity of the incident X-ray beam by half. The HVL is an estimate of the penetrating power of the X-ray beam which means that the higher the HVL the more penetrating the X-ray beam is.

2.3.1 How to measure HVL

A dosimeter such as a thimble ionisation chamber should be positioned at the isocentre of the X-ray beam or at the surface of the detector. If possible, the scanner should be set to operate in 'service mode' so that the X-ray tube is stationary. If this is not possible, then alternatives should be considered, such as the possible use of the 'scout' mode. Alternatively the scanner can be operated under normal conditions with care taken in setting up the dosimeter and the filters. A typical protocol for measuring HVL should be followed^{vi}, in which the transmission through known thicknesses of high purity aluminium is assessed. Using this HVL measurement and knowledge of the X-ray tube design, the total filtration can be estimated from look-up tables^{vii}. HVL is measured directly on several modern dose/kV meters as an alternative to this method.

2.4 Radiation Field of View

The field of view (FOV) of a dental CBCT scanner is usually defined at the isocentre. The scanner should be set to operate in 'service mode' and a film or a CR cassette can be placed at the isocentre and exposed to different field sizes. The size of the film or the CR cassette should be chosen so as to extend over the nominal dimensions of the FOV. The dimensions of the imaged field can be measured and compared to the nominal FOV, as quoted by the manufacturers, and the dimensions of the FOV measured at baseline. If the manufacturers state that it is necessary to irradiate beyond the nominal FOV for the purposes of image reconstruction this should be taken into account.

If the scanner cannot be operated at the 'service mode', then the film or the CR cassette could be placed on the detector and exposed to the maximum and different FOVs. If the distance of the focal spot to the detector is known, then the dimensions of the nominal FOV on the detector can be calculated and compared to the imaged FOV. Alternatively, two sets of thermoluminescent dosimeters (TLDs) could be placed using holders at the isocentre with the first set placed vertical and the second set placed parallel to the z-axis and exposed to one FOV at a time. The number of TLDs should be chosen so as to extend over the nominal dimensions of the FOV. The TLDs are read out and the dimensions of the irradiated FOV are compared with the dimensions of the nominal FOV.

In addition, it should be confirmed that the X-ray beam is contained within the detector. A film or a CR cassette should be placed on the surface of the detector and the edges of the active area of the detector should be marked on the film or CR cassette and then exposed to radiation. The radiation field should not extend beyond the marked edges on the film or the CR cassette.

2.5 X-ray beam alignment

This test is to assess the coincidence of the centre of the radiation and imaged FOV with the isocentre as defined by the alignment lasers or the scout view.

Any radiopaque object positioned at the isocentre allows for a measurement of the distance between the imaged object and the centre of the imaged FOV using the measuring tool of the scanner's software. Note that the accuracy of this measurement is reliant on the correct calibration of the measurement software (see section 4.6) and the voxel size of the reconstructed image.

2.6 Leakage

Radiation is emitted from all directions from the focal spot, not just in the direction of the primary X-ray beam. The tube housing is designed to attenuate the radiation outside the main beam so that patient and staff are not significantly exposed. This source of secondary radiation is known as leakage.

On standard X-ray equipment, leakage is measured during commissioning, usually by a medical physics expert, to confirm that the tube head design and construction is adequate. It should also be measured if physical damage to the tube head has occurred or the tube head has been dismantled during repair.

The measurement of leakage on a dental CBCT is problematic and can only reliably be achieved if the movement of the tube head can be stopped (likely to be available in 'service mode' only) and the primary beam can be blocked either by the use of collimators or a lead block at least 1mm thick placed as close to the tube window as possible. If this can be achieved, standard methods for leakage measurement can be applied^{viii}, involving the identification of areas of leakage and the measurement of dose rate at these areas. When interpreting the results, due regard should be made to the effectiveness of the attenuation applied at the tube window.

If the movement of the tube head cannot be stopped, securely fixing a lead block as close to the tube window as possible should still allow meaningful measurements of secondary radiation to be made at accessible points adjacent to the unit. These results will give an indication of whether the leakage from part of the tube housing is higher than expected. The use of film or computed radiography plates around the tube housing can also be useful in detecting small areas in which there is less shielding, or where the shielding is absent altogether. If detected, measurements of secondary radiation can be focussed in these areas.

3 Patient dose

Knowledge of patient dose is essential for clinicians who are making the decision regarding the justification of the exposure. It is also important to ensure that doses are optimised and in line with any national and international guidelines. The dose quantity 'effective dose' gives an indication of radiation risk and can be compared to doses from other radiation sources. However, effective dose cannot readily be measured and must be inferred from more easily measurable dose quantities.

3.1 Dose measurement

A variety of dose indices are used to characterise patient dose.

3.1.1 CTDI

For CT scanners the CT dose index (CTDI) is usually used. This is a measurement of the dose integrated across the dose profile along the patient's length. It is measured using a pencil detector either in air or in a perspex phantom^x. Such a dose index has drawbacks for use in dental CBCT units due to the greater beam size and asymmetry of the dose distribution. However, if a CTDI is quoted by the manufacturers, it is suggested that this be measured by the medical physics expert at commissioning for comparison with the specification.

3.1.2 CBCT dose index

The SEDENTEXCT project has investigated the use of a dose index obtained from measurements using a small volume dosimeter in a Perspex phantom. This is measured at points across the X-Y plane in the centre of the Z axis.

Measurements can be performed using an ion chamber or TLDs, within a suitable PMMA phantom (diameter 16cm is recommended). Two CBCT dose indices are currently proposed. Index 1 requires measurements along a diameter of the phantom (Figure 1) and is calculated as the mean of the readings. Index 2 involves measurements at the centre of the phantom and at points around the periphery. Index 1 allows the measurement of an index for on-axis and off-axis exposures, and full and partial dose distributions simply by rotating the phantom in such a way that the isocentre of the x-ray beam lies on the measuring diameter as shown in Figure 1. Index 2 is only suitable for symmetrical dose distributions.

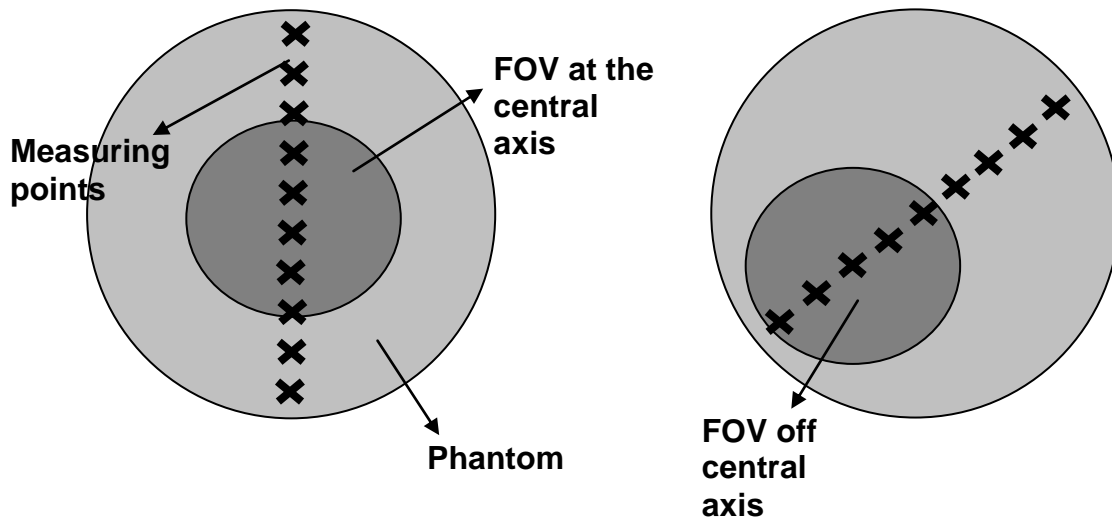


Figure 1 Measurement points for Index 1

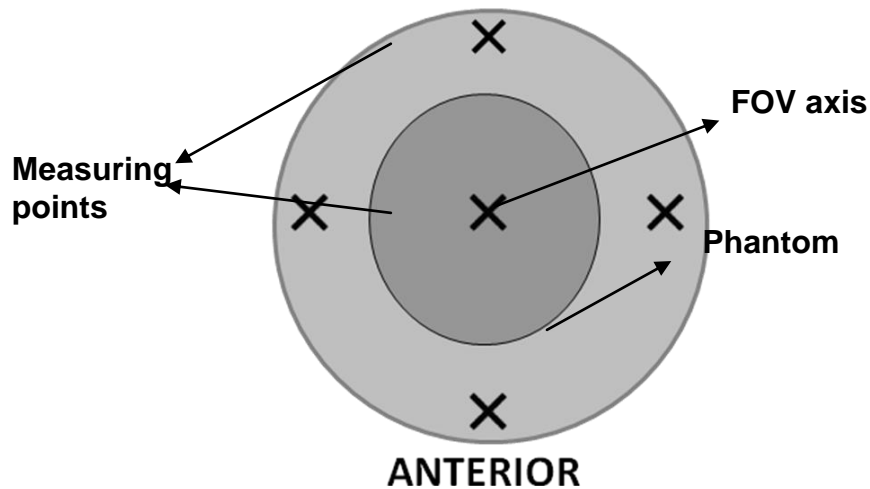


Figure 2 Measurement points for Index 2

Such indices can be used to monitor the reproducibility of the dose distribution over time, to relate to manufacturer's specification and national or international diagnostic reference levels if set using a dose index.

3.1.3 Dose area product (DAP)

The product of the dose in the beam multiplied by the area of the beam at that point is known as the dose area product (DAP) and is a dose index routinely used in panoramic and cephalometric radiography, as well as in general radiography and fluoroscopy.

DAP can readily be measured by the medical physics expert using either a calibrated ionisation chamber that integrates the dose across the primary beam (DAP meter) or by measuring dose and beam size at a fixed point. Care should be taken on units where the beam size changes during the scan and a suitable DAP meter must be used for these units.

If a DAP reading is provided on the equipment readout, the medical physics expert should confirm the accuracy of such a readout. The readout may then be used by the dentist to audit and monitor dose and compare to any national or international audit levels (see diagnostic reference levels).

If no DAP reading is provided, the medical physics expert should provide the DAP readings for all standard settings of the equipment so the dentist can compare the levels to any national or international audit levels (see diagnostic reference levels).

3.2 Diagnostic reference levels

The European Medical Exposures Directive requires that diagnostic reference levels are set and used as part of the optimisation process. Exactly how this requirement is applied varies from country to country depending on how it has been implemented into national legislation. However, the overall aim is that patient dose is audited and the dose for a typical patient is compared to past levels and any national and international levels. This will give the dentist

confidence that doses in their practice are not unnecessarily drifting upwards and that they are in line with accepted levels.

Diagnostic reference levels may be set using a variety of dose indices. The UK Health Protection Agency has recommended the use of dose area product (DAP) and has proposed setting reference levels for the UK for both adult and child procedures. The adult level is for the clinical protocol for the placement of an upper first molar implant in a standard male patient and the child level is for the clinical protocol used to image a single impacted maxillary canine of a 12 year old male. Based on current national audit data an initial achievable level of 250 mGy cm² is proposed and further data is requested so that national reference levels for both adult and child can be set.

It is recommended that clinical dose levels are determined in a practice (by measurement of standard protocols or by patient dose audit if dose index readouts are provided by the equipment) and compared to past results and any national and international levels when set. Dose levels higher than these standards merit investigation as this would suggest that dose is not optimised.

4 Quantitative image quality performance

A range of image quality indicators can be measured using phantoms designed for such measurements. A variety of different phantoms are available.

Phantoms, such as the Catphan, designed for use on CT scanners can be used for dental CBCT units but are difficult to position and tend to use soft tissue-equivalent materials for the more accurate evaluation of grey scale accuracy.

Dental imaging has a few specific requirements (e.g. hard tissue visualisation and sub-millimetre spatial resolution) which are not assessed by phantoms not specifically designed for the purpose. Some manufacturers provide phantoms with their scanners and the SEDENTEXCT project has designed a phantom specifically with dental CBCT units in mind.

In addition, software tools are required to analyse the images of the phantom. These may be available as part of the image viewing software or may be separately provided with the phantom. The SEDENTEXCT phantom is provided with standard software for image analysis.

Acquisition of such a phantom and software tools is essential if the image quality measurements are to be performed. MPEs should normally have access to such phantoms and software and will be able to carry out these measurements.

Note that whilst most systems exhibit a linear relationship between image pixel value and object density within a single scan, the use of histogram shifting by some units means that this is not always the case from scan to scan. Care should be taken when comparing uncorrected data across scans or from unit to unit.

4.1 Image density values

A clinically useful image relies on the system's ability to distinguish between and clearly display the different materials in an image. The accuracy with which a system can continue to do this over time can be determined quantitatively.

4.1.1 Setting a baseline

- Acquire an image of the image density value section of the phantom. This should be an area in which there are many different materials clearly distinguished from one another
- Draw a region of interest in each of the different materials and record the mean pixel value and standard deviation in each

4.1.2 Routine measurements

- In future visits, expose the same test object using the same protocol, draw a region of interest in each of the different materials and record the mean pixel value and standard deviation in each
- Compare the mean pixel value for each material with that measured on the first visit

4.2 Contrast detail assessment

Assessing a system's ability to display details of known varying contrast can give important information as to the deterioration of image quality over time. A phantom containing objects with a range of different sizes and/or contrasts is required.

4.2.1 Setting a baseline

- Acquire an image of the contrast detail section of the phantom. This should be an area in which there are various details of the same material that vary in diameter and depth, or various details of different materials
- The simplest check of contrast detail is counting the number of details that can be clearly resolved on a reporting monitor
 - It may be useful to derive a single value for contrast detail assessment, for example the threshold detection index, the image quality factor or the contrast to noise ratio^{xii}. Action levels will depend on the test object and scoring methodology used
 - Some phantoms may provide software that calculates contrast detail values after analysing images. In these cases, follow the instructions that come with the phantom

4.2.2 Routine measurements

- Acquire an image of the contrast detail section of the same phantom using the same exposure protocol as at baseline
- Count the number of details on the image using the same monitor as at baseline where possible
 - If a threshold detection index, image quality factor or contrast to noise ratio is being used, compare with the baseline results
 - If automated scoring with phantom software is being used, results should be compared with baselines

Scoring test objects by eye is very subjective. It should be ensured that where there are different personnel scoring the details, they use a similar methodology.

4.3 Uniformity and artefacts

It is important that the entire detector is capable of producing a useful image, and so it must be ensured that there are no significant areas of damage or problems with detector calibration that could lead to artefacts in acquired images. Similarly it must be confirmed that damaged or dead pixels are appropriately corrected for in the final image.

4.3.1 Where a QC phantom is available:

- Acquire an image of the uniformity section of the phantom. This should be a large homogeneous area so that it can be assured that any deviations on the image are the result of the imaging system and not the phantom itself
- A visual check of the uniformity of the image will reveal any significant uniformity problems
- Where quantitative tools are available, draw a region of interest in the centre of the test object and then four evenly spaced regions around the periphery and measure the mean pixel value in each. Assess the image uniformity using the results

4.3.2 Where no QC phantom is available:

- Acquire an image with nothing in the beam. Be aware that this could give odd images on some scanners if the reconstruction relies on a head or equivalent phantom being present. In these cases consider the use of a scout view
- A visual check of the uniformity of the image will reveal any significant uniformity problems. In this case, some windowing of the image may be necessary to better assess uniformity
- Where quantitative tools are available, draw a region of interest in the centre of the test object and then four evenly spaced regions around the periphery and measure the mean pixel value in each. Assess the image uniformity using the results

4.4 Noise

There are many processes that could affect the quality of a clinical image, including tube output, detector efficiency and image processing. A quantitative assessment of the noise in an image can identify any deterioration in image quality with time and help determine the cause of the deterioration.

4.4.1 Setting a baseline

- Acquire an image of the uniformity section of the phantom. This should be a large homogeneous area so that it can be assured that any deviations on the image are the result of the imaging system and not the phantom itself
- Draw a region of interest in the centre of the test object, with diameter no greater than one fifth the diameter of the test object. Record the standard deviation

- Repeat for five consecutive axial slices and calculate the average standard deviation.

4.4.2 Routine measurements

- Acquire an image of the uniformity section of the same phantom using the same protocol as at baseline
- Draw a region of interest in the centre of the test object, as close in size and position to that at baseline as possible, and record the average standard deviation across five consecutive axial slices

Further analysis:

Consideration should be given to the calculation of a signal to noise ratio in addition to the noise measurements described above. The information provided by signal to noise ratios can be useful in investigating potential problems with the system where they are suggested by noise measurements alone.

4.5 Spatial Resolution

Spatial resolution is a measure of the ability of the system to detect small high contrast detail.

4.5.1 Limiting resolution

This test measures the smallest high contrast detail that can be detected, usually by using a phantom in which small lines get closer and closer together.

Method

Place a suitable object made of a high contrast material on the detector and expose at clinically relevant exposure factors. Magnify the reconstructed image of the test object and optimise the window level. Score the number of resolvable groups of lines and convert to the corresponding resolution. Be sure to use the same exposure factors as at baseline year on year.

4.5.2: Modulation Transfer Function (MTF)

Measurement of the limiting resolution will assess the system's ability to transfer the high frequencies (finest details) but it does not provide any indication on how other frequencies are transferred. This can be assessed by measuring the modulation transfer function (MTF) of the system. The MTF can be calculated by measuring the Point Spread Function (PSF) or the Edge Spread Function (ESF).

The PSF can be measured directly by imaging a high contrast wire. The wire is embedded in a suitable medium and placed perpendicular to the scan plane. The PSF is obtained by plotting the pixel values across the image cross-section of the image of the wire. Resolution can be measured directly from the PSF by measuring the full width at half maximum (FWHM).

The ESF is measured by imaging an edge of a block of material embedded in a suitable material with the face of the block perpendicular to the scanned plane. The ESF is obtained by plotting the pixel values across the image.

Differentiating the ESF will give the Line Spread Function (LSF). The LSF can be used to assess the spatial resolution of the system similar to the PSF.

The MTF can be calculated as the modulus of the Fourier transform of the PSF or the LSF. The values quoted are the frequencies at which the modulation falls to 50% or 10% of its initial value.

A more detailed description of the MTF method is given in the IPEM Report 32, Part VII.^x

4.6 Geometric Accuracy

Where it may be clinically useful to perform measurements of distance or angle on an image, it must be ensured that measurements made on a system accurately reflect true distances and angles. A phantom is required that contains an area with objects at known distances and angles from one another.

- Acquire an image of the geometric accuracy section of the phantom.
- Where quantitative test tools are available, measure distances and angles across a variety of the objects within the phantom
- Compare the measured values with known distances and angles. A more detailed analysis can be performed by calculating the aspect ratio and pixel pitch if required.
- Ensure the aspect ratio is correct by calculating measured x / measured y for distances of the same intended length. The ratio should be 1 ± 0.04
- Ensure the pixel pitch is as stated by the manufacturer by calculating measured distance (mm) / number of pixels covering the measured distance. Measure the pixel pitch for various distances in the x and y axes

5 Display equipment

Regardless of the quality of the x-ray equipment with which an image is acquired, a clinical image can only be digitally displayed as well as the monitor on which it is viewed is capable of. It is essential therefore to ensure that any monitor that is used to report on clinical images is well set up and subject to regular QC.

The QC programme outlined in the report of the AAPM task group 18^{xi}, or equivalent, is an appropriate methodology for MPE tests. Regular in-house checking of the display monitors should also be performed, as follows:

5.1 General condition

- A suitable test pattern, such as an AAPM TG18 or SMPTE image, should be installed on the computer and viewed on the monitor, which should be clean
- It should be ensured that all distinct greyscale levels on the test pattern can be individually resolved. The small black and white squares within the larger black and white squares should also be clearly resolved

- Where two monitors are used for reporting, it should be ensured that the perceived contrast of each of the distinct greyscale levels is consistent between the two

5.2 Monitor resolution

- It should be ensured that all of the bars on each of the resolution patterns on the AAPM TG18 or SMPTE test image can be clearly resolved

Summary

	Test	Priority	Level of expertise*	Suggested frequency	Action levels**
X-ray tube and generator	Output repeatability	Essential	MPE	12 monthly	Mean $\pm 10\%$
	Output reproducibility	Essential	MPE	12 monthly	Baseline $\pm 10\%$
	Filtration	Essential	MPE	When new, if output changes or tube head dismantled	< 2.5mm aluminium (of which 1.5mm should be permanent)
	Tube potential	Essential	MPE	12 monthly	> $\pm 5\%$ of intended kV
	Field size and alignment	Essential	MPE	12 monthly	> 10% expected field size
	Leakage	Essential	MPE	When new and if damage suspected	> 1000 μ Gy hr ⁻¹ at maximum tube rating.
Quantitative image Quality	Image density values	Recommended	In house/MPE	Monthly	> 10% from baseline
	Uniformity and artifacts	Essential	In house	Monthly	Visible artefacts on the image or > $\pm 10\%$ of the mean
	Noise	Recommended	In house/MPE	12 monthly	> $\pm 10\%$ from baseline
	Limiting resolution	Essential	In house/MPE	12 monthly	> $\pm 20\%$ from baseline
	Contrast detail	Recommended	In house/MPE	12 monthly	Dependent on method used.
	Geometrical accuracy	Essential	In house/MPE	12 monthly	Within ± 0.5 mm and $\pm 2^\circ$
Display specific	General condition	Essential	In house	Monthly	Failure to resolve different contrasts in test pattern/ not consistent between monitors
	Monitor resolution	Recommended	In house	Monthly	Not consistent with baseline image
Patient dose	Patient dose index	Recommended	MPE	12 monthly	Outside $\pm 15\%$ of manufacturer's specification
	Patient dose audit	Essential	In house/MPE	At least 3 yearly	> national or international reference level

Notes

* **Level of expertise:** MPE indicates that this test would normally require the input of a medical physics expert with sophisticated test equipment whereas in house indicates that the tests can normally be performed by clinic staff using standard phantoms

** **Action level:** Results outside these levels should be investigated and action taken. The advice of a medical physics expert or service engineer may be required

N.B. This table represents initial guidance based on current experience of dental CBCT units. It should be kept under critical review as experience is gained in testing such units.

References

- ⁱ Council Directive 97/43/Euratom of 30 June 1997 on health protection of individuals against the dangers of ionizing radiation in relation to medical exposure Official Journal of the European Communities No L 180/11 1997
- ⁱⁱ Draft Euratom Basic Safety Standards Directive – Version 24 February 2010
http://ec.europa.eu/energy/nuclear/radiation_protection/doc/art31/2010_02_24_draft_euratom_basic_safety_standards_directive.pdf
- ⁱⁱⁱ IPEM report 91 Recommended standards for the routine performance testing of diagnostic X-ray imaging systems IPEM 2005
- ^{iv} HPA-RPD-065 Recommendations for the design of X-ray facilities and quality assurance of dental Cone Beam CT (Computed tomography) systems JR Holroyd and A Walker Health Protection Agency 2010
- ^v SEDENTEXCT <http://www.sedentextct.eu/>
- ^{vi} IPEM Quality assurance in dental Radiology Report No 671995
- ^{vii} Cranley K. & Fogarty G.W.A. 1988 The measurement of total filtration of diagnostic X-ray tubes BJR 61
- ^{viii} IEC (International Electrotechnical Commission) 2008 Medical electrical equipment - Part 1-3: General requirements for basic safety and essential performance - Collateral Standard: Radiation protection in diagnostic X-ray equipment. IEC publication 60601-1-3.
- ^{ix} IPEM Report 32 Measurement of the Performance characteristics of diagnostic X-ray systems used in medicine Part III Computed Tomography X-ray scanners 2nd Ed IPEM 2003
- ^x IPEM Report 32 Measurement of the Performance characteristics of diagnostic X-ray systems used in medicine Part VII Digital imaging system IPEM 2010
- ^{xi} Samei E, Badano A, Chakraborty D, Compton K, Cornelius C, Corrigan K, Flynn MJ, Hemminger B, Hangiandreou N, Johnson J, Moxley M, Pavlicek W, Roehrig H, Rutz L, Shepard J, Uzenoff R, Wang J, Willis C. Assessment of Display Performance for Medical Imaging Systems, Report of the American Association of Physicists in Medicine (AAPM) Task Group 18, Medical Physics Publishing, Madison, WI, AAPM On-Line Report No. 03, April 2005.
- ^{xii} NHS Breast Screening Programme – Commissioning and routine testing of full field digital mammography systems . NHSBSP equipment report 0604, April 2009.